

American Academy of Otolaryngology—
Head and Neck Surgery Foundation

Primary Care Otolaryngology

Third Edition



AMERICAN ACADEMY OF
OTOLARYNGOLOGY—
HEAD AND NECK SURGERY

F O U N D A T I O N

©2011 All materials in this eBook are copyrighted by the American Academy of Otolaryngology—Head and Neck Surgery Foundation, 1650 Diagonal Road, Alexandria, VA 22314-2857, and are strictly prohibited to be used for any purpose without prior express written authorizations from the American Academy of Otolaryngology—Head and Neck Surgery Foundation. All rights reserved.

For more information, visit our website at www.entnet.org.

Print: First Edition 2001, Second Edition 2004

eBook Format: Second Edition 2004, Third Edition 2011

ISBN: 978-0-615-46523-4

Preface

Dr. Gregory Staffel first authored this short introduction to otolaryngology for medical students at the University of Texas School for the Health Sciences in San Antonio in 1996. Written in conversational style, peppered with hints for learning (such as “read an hour a day”), and short enough to digest in one or two evenings, the book was a hit with medical students.

Dr. Staffel graciously donated his book to the American Academy of Otolaryngology—Head and Neck Surgery Foundation to be used as a basis for this primer. It has been revised and edited, and is now in its third printing. This edition has undergone an extensive review, revision, and updating. We are grateful to the many authors and reviewers who have contributed over the years to the success of this publication. We believe that you, the reader, will find this book enjoyable and informative. We anticipate that it will whet your appetite for further learning in the discipline that we love and have found most intriguing. It should start your journey into otolaryngology, the field of head and neck surgery.

Enjoy!

Mark K. Wax, MD, Editor

Coordinator, Education Steering Committee
American Academy of Otolaryngology—Head and Neck Surgery
Foundation

Contents

1. Introduction to Clinical Rotation	4
2. Evaluating and Keeping Track of Patients.....	9
3. Presenting on Rounds.....	17
4. ENT Emergencies.....	21
5. Otitis Media	31
6. Hearing Loss	41
7. Dizziness.....	49
8. Facial Nerve Paralysis	55
9. Rhinology, Nasal Obstruction, and Sinusitis.....	60
10. Allergy	69
11. How to Read a Sinus CT Scan	74
12. Maxillofacial Trauma	79
13. Facial Plastic Surgery	86
14. Salivary Gland Disease	93
15. Thyroid Cancer	98
16. Head and Neck Cancer.....	105
17. Skin Cancer.....	115
18. Pediatric Otolaryngology	120

Introduction to Clinical Rotation

The goals of this book are to make good clinicians out of medical students and to teach the basics of Otolaryngology—Head and Neck Surgery.

Sometimes individuals have trouble transitioning from being second-year medical students, where they are truly students, to becoming healthcare professionals. This metamorphosis over the third and fourth years of medical school involves learning how to carry yourself and act as a healthcare professional.

To meet this first goal and become a good clinician, it is helpful for students to be carefully observant of their professors in important but unnoticed aspects, such as their demeanor, comments, and interaction with house staff and patients. Students learn a lot through observing care of patients. The process starts with the student's appearance (clothing and grooming), punctuality, composure, acceptance of responsibility, and interactions with patients and other healthcare team members. You need to really listen to patients.

It can be difficult to understand a medical student's role in the healthcare team. Work to become an active member of the team. Interns, residents, and attendings are overworked and spread quite thin. However, medical students frequently have extra time to spend with their patients, talking to the patients about their past medical problems, family, and social history as they pertain to their disease process. Most important, work toward establishing a true patient-physician relationship. This type of relationship establishes the medical student as an important part of the healthcare team, beneficial to the overall care provided to the patient. For the medical student, it also establishes long-term behaviors that translate into the development of an excellent future physician.

A few basic rules will help you to become a good clinician. During the third year, there may be conflicting responsibilities, such as being at a lecture while needing to draw a patient's blood. In general, the priority

should be the care of the patient. If it is an important blood test and you cannot get someone to do it for you, you may need to miss the lecture. These situations don't actually come up that often, and if patient care is the main goal, over the long run, most people will respect these decisions.

There are two kinds of physicians: those who read and those who don't. Read about your patients' conditions. You should read textbooks because they cover the basics, and 90 percent of people do not know what is in them. Articles are for later. It does not matter which textbook you read, because if the information is important, it will come up again in later reading. If the information is unimportant, it will not come up very often.

So now you have four patients and you go home. You got up at 5:00 a.m. to make it to rounds. You get home at 7:00 p.m. after your last post-op note. After you have petted the dog and had something to eat, it is 8:30. You deserve a break, so you watch TV for an hour. You are ready to read, and recall from your notes that your patient has hypertension, chronic obstructive pulmonary disease, diabetes, and a pleomorphic adenoma. There is no way you can read about all that tonight, and you have to get up at 5:00 a.m. tomorrow. So you go to bed, and the next morning you do not really know why we even treat asymptomatic hypertension in the first place. Solution: Read for an hour every day. Afterward you can do whatever you want and not feel guilty or overwhelmed. You will also be amazed at how well you do. Most students do not average anywhere near an hour of daily reading. Read about your patients. Remember Darwin's theory of medical education: "It cannot be that rare if you are seeing it."

We know that you, as medical students, aspire to the highest ideals of professionalism. We know that you will always have a neat appearance and a pleasant personality. We know that you will do completely thorough histories and physicals. You will be very compassionate to all your patients and coworkers, and you will always be willing and ready to learn. It has been our experience that all students know this is expected of them. However, there is one important caveat that is often not addressed in medical education: It is as much your responsibility to know your limitations as it is to know about treating patients. If you are trying hard, reading an hour every day, and truly interested, then if you are asked a question to which you do not know the answer, it is perfectly legitimate, and indeed expected, that you simply answer, "I don't know." Nobody knows everything.

If you use the information you already have, you will often do surprisingly well if you guess at an answer. But if your answer is only a guess, qualify it by pointing out that you do not specifically know the answer. Integrity—

CHAPTER 1

an absolute commitment to honesty—is a prerequisite for becoming a physician.

Although you may not know that much yet in your clinical career, you have one secret weapon as a student: enthusiasm. Residents are often tired and grouchy, as you probably have noticed, but having an enthusiastic student around makes a difference.

The second goal of this book is to teach you a little about common ear, nose, and throat (ENT) problems. Since the great majority of you will not become otolaryngologists, it becomes much more important for you to understand how to recognize potentially dangerous problems that should be referred to an otolaryngologist, as well as how to manage uncomplicated problems that can be taken care of at the primary care level.

INTRODUCTION TO CLINICAL ROTATION

QUESTIONS

1. Your highest professional priority throughout your third year and the rest of your career should be _____.
2. One way to learn as much as possible, without feeling overwhelmed, during the third year is to _____.
3. When faced with two conflicting responsibilities, _____ should always be your highest priority.
4. If you guess at a question on rounds, you should _____.
5. The key to a happy career in medicine is to make _____ your highest professional priority.
6. In all countries of the world, a common vein through medicine is to keep as the first priority _____.

ANSWERS

1. The care of the patient
2. Read for an hour every day
3. The care of the patient
4. Qualify your answer
5. The care of the patient
6. The care of the patient

Evaluating and Keeping Track of Patients

Taking an Otolaryngology History and Performing a Head and Neck Exam

The ENT history begins with the **chief complaint** followed by a description of the **location, duration, frequency, and quality** of the presenting symptoms. In addition, always inquire about the **aggravating and relieving factors**. Next, ask the patient about **associated symptoms**. The following is a short list that can be used:

- General/systemic symptoms (fever, chills, cough, heartburn, dizziness, etc);
- Otologic (tinnitus, otalgia, otorrhea, aural fullness, hearing loss, vertigo);
- Facial (swelling, pain, numbness);
- Nasal (congestion, rhinorrhea, post-nasal drip, epistaxis, decreased smell);
- Sinus (pressure, pain);
- Throat (soreness, odynophagia, dysphagia, globus sensation, throat clearing);
- Larynx (vocal changes or weakness, hoarseness, stridor, dyspnea); and
- Neck symptoms (pain, lymphadenopathy, torticollis, supine dyspnea).

The head and neck exam involves inspection (and palpation if practical) of all skin and mucosal surfaces of the head and neck. Otolaryngologists utilize special equipment to better assess the ears, nose, and throat. A binocular microscope provides an enlarged, three-dimensional image, giving the physician a superior view of the ear canal and tympanic membrane. The microscope also permits the bimanual removal of wax and foreign bodies. Indirect mirror exam with a headlight permits examination of the

larynx, hypopharynx, and nasopharynx. Fiberoptic instruments provide a similar ability to examine these regions, but with superior optics.

The Ear

Assess the **external auricle** for congenital deformities, such as microtia, promin auris, or preauricular pits. The external auditory canal should be examined by **otoscopy** after being thoroughly cleaned if it is blocked by cerumen. The canal should be assessed for swelling, redness (erythema), narrowing (stenosis), discharge (otorrhea), and masses. The tympanic membrane is normally pearly gray, shiny, translucent, and concave. Changes in the appearance of the eardrum may indicate pathology in the middle ear, mastoid, or eustachian tube. White patches, called **tympanosclerosis**, are often clearly visible and provide evidence of prior significant infection. An erythematous, bulging, opacified tympanic membrane indicates acute bacterial otitis media. A dull, retracted, amber eardrum can be a sign of serous otitis. If a perforation is present, then the middle ear mucosa may be viewed directly. Healed perforations are often more transparent than the surrounding drum and may be mistaken for actual holes.

Pneumatic otoscopy should be performed to observe the mobility of the tympanic membrane with gentle insufflation of air. Mobility may be limited by scarring, middle ear effusion, or perforation. Eustachian tube function may be assessed by watching the eardrum as the patient executes a gentle Valsalva.

Tuning forks can be used to grossly assess hearing and to differentiate between conductive and sensorineural hearing loss. A tuning fork placed in the center of the skull (**Weber test**) will normally be perceived in the midline. The sound will lateralize and be perceived as louder on the affected side in cases of conductive hearing loss. If a sensorineural loss exists, the sound will be perceived in the better or normal hearing ear. The tuning fork is then placed just outside the external auditory canal for the **Rinne's test** of air conduction hearing. Placing the base of the tuning fork over the mastoid process allows bone conduction hearing to be assessed. In conductive hearing loss, the tuning fork is heard louder behind the ear (bone conduction is better than air conduction in conductive hearing losses).

A proper, complete assessment of hearing requires **audiometry**. This is indicated in any patient with chronic hearing loss, or with acute loss that cannot be explained by canal occlusion or middle ear infection. It is also an integral part of the evaluation of the patient with vertigo.

The Nose

Anterior rhinoscopy should be performed utilizing a bivalve speculum. Evaluate the septum and anterior portions of the inferior turbinates. Topical vasoconstriction with oxymetazoline permits a more thorough examination and allows for assessment of turbinate response to decongestion. Nasal patency may be compromised by swollen boggy turbinates, septal deviation, nasal polyps, or masses/tumors. The remainder of the nasal cavity can be more carefully examined by performing **flexible fiberoptic or rigid nasal endoscopy**. This allows a more thorough evaluation of the nasal cavity and mucosa for abnormalities, including obstruction, lesions, inflammation, and purulent sinus drainage. The sense of smell is rarely tested due to the difficulty in objectively quantifying responses. However, ammonia fumes can be useful for distinguishing true anosmics from malingerers because ammonia will stimulate trigeminal endings, and thus produce a response in the absence of any olfaction.

The Mouth

An adequate light and tongue depressor are necessary for examining the mouth. The tongue depressor should be used to systematically inspect all mucosal surfaces, including the **gingivobuccal sulci**, the **gums** and **alveolar ridge**, the **hard palate**, **soft palate**, **tonsils**, **posterior oropharynx**, **buccal mucosa**, **dorsal** and **ventral tongue**, **lateral tongue**, and the **floor of mouth**. Dentures should always be removed to permit a complete examination. The parotid duct orifice (**Stenson's duct**) can be seen on the buccal mucosa, opposite the upper second molar. Massage of the parotid gland should express clear fluid. The submandibular and sublingual glands empty into the floor of the mouth via **Wharton's ducts**. Complete examination of the mouth includes bimanual palpation of the tongue and the floor of the mouth to detect possible tumors or salivary stones.

The Pharynx

The posterior wall of the oropharynx can be easily visualized via the mouth by depressing the tongue. Inspection of the nasopharynx, hypopharynx, and larynx requires an indirect mirror exam or use of a flexible fiberoptic rhinolaryngoscope. All mucosal surfaces are evaluated, to include the eustachian tube openings, adenoid, posterior aspect of the soft palate, tongue base, posterior and lateral pharyngeal walls, vallecula, epiglottis, arytenoid cartilages, vocal folds (false and true), and pyriform sinuses. Vocal fold mobility should be assessed by asking the patient to alternately phonate and sniff deeply. The glottis opens with inspiration (sniffing) and closes for phonation.

The Salivary Glands

The parotid and submandibular glands should be inspected and palpated to detect enlargement, masses, and/or tenderness.

The Neck

The normal neck is supple, with the laryngotracheal apparatus easily palpable in the midline. A complete examination should include external observation for symmetry and thorough palpation of all tissue for possible masses. The exact position, size, and character of any mass should be carefully noted, along with its relationship to other structures in the neck (thyroid, great vessels, airway, etc.).

Cranial Nerves

A complete head and neck exam includes testing of cranial nerves (CN II–XII). A pocket eye chart should be used to test the patient's vision (**Optic - CN II**). Extraocular eye movements should be tested, along with the pupillary response to light (**oculomotor, trochlear, and abducens—CN III, IV, and VI, respectively**). The **trigeminal nerve (CN V)** can be tested by testing areas of the face using a pin and a wisp of cotton. Having the patient clench his teeth and then open his jaw against resistance also tests CN V. Test the **facial nerve (CN VII)** by having the patient raise his eyebrows, squeeze his eyes shut, scrunch his nose, pucker his lips, and smile. The **vestibulocochlear nerve (CN VIII)** can be tested with a tuning fork. **CN IX (glossopharyngeal) and CN X (vagus)** control swallowing, the gag reflex, and speech, and so are tested by observing these actions. Have the patient swallow and say “ah, ah, ah.” You can also touch the back of the throat with a tongue depressor to check the gag reflex. Assessment of vocal cord function by flexible fiberoptic laryngoscopy also provides information on the status of the vagus nerve. Assess the function of the **spinal accessory nerve (CN XI)** by asking the patient to push his head laterally against resistance and shrug his shoulders against resistance. Finally, assess the **hypoglossal nerve (CN XII)** by having the patient stick out his tongue. Deviation to one side indicates a weakness or paralysis of the nerve on that side.

Differential Diagnosis

Every time you see a new patient, you begin to formulate a **differential diagnosis** for him or her. Most of us begin by doing this randomly, usually the **five most recent diagnoses** we have **seen for this set of symptoms and physical findings**. This works when you have seen several thousand patients, but it is not as useful if you have seen only 100 or so. A useful

EVALUATING AND KEEPING TRACK OF PATIENTS

trick is to use an acronym that represents a **system based on disease categories** (such as “Vitamin C” in the accompanying box).

Try it for yourself, and practice using it on all your patients. You will find that this or another system will be a big help in organizing your thoughts when you are confused or during high-stress rounds.

V	ascular
I	nfectious
T	raumatic
A	utoimmune (or anatomic)
M	etabolic
I	atrogenic or idiopathic
N	eoplastic
C	ongenital

On the otolaryngology service, most patients spend very little time in the hospital, and keeping track of everything about each patient is not worth your time. However, certain key information is needed on each patient, and you should learn how to keep this information in a usable format. Physicians need a good system for keeping track of patients, and we offer this system to help you with your inpatient duties.

Perhaps most important, a list of patients and their diseases is an ideal way to review and select topics for additional reading. (Remember, you are reading an hour every day.)

One system involves **3 x 5-inch note cards**. The basic idea is shown in Figures 2.1 and 2.2. Other alternatives include using Personal Digital Assistants (PDAs) or other mobile devices with commercial data software. This system allows storage of the data, so should you wish to “retrieve” a memorable patient experience, the information will be available.

What you will notice if you look closely and understand the system is that you know everything about the patient during their whole stay. When the chief resident asks, “What was his creatinine three days ago?” you know it!

Name: John Smith	MR# 12-345-6785	Room # 233A
64 yo white male w/tonsil Ca, CAD, HTN, DM		
History		
NKDA		
Meds: start/stop date		
cefazolin, metronidazole, 8/24		
Ba swallow 8/30, no extravasation		
Study: date, results		
Urine 8/27, 100k/ml E. coli		
Culture: date		
results		
Path: SCCa, margins, 8/22 I.N -		

Figure 2.1.

CHAPTER 2

8/24 POD 1: cefazolin / metronidazole Tmax: 38.5 i/o: 2700/1380 JPs: A 170, B 125 (Labs...)	8/25 POD 2: cefazolin / metronidazole (etc...)	
---	---	--

Figure 2.2.

medicine that is outlined in the Health Insurance Portability and Accountability Act (HIPAA) of 1996.

Please be aware that identifiable patient information is protected, and even students are responsible for protecting patient privacy. This is an important aspect of

EVALUATING AND KEEPING TRACK OF PATIENTS

QUESTIONS

1. Vitamin C is one way of organizing a differential diagnosis list.

V _____

I _____

T _____

A _____

M _____

I _____

N _____

C _____

2. A complete head and neck exam includes examination of _____, as well as the _____.

15

ANSWERS

1. Vascular

Infectious

Traumatic

Autoimmune (or anatomic)

Metabolic

Iatrogenic or idiopathic

Neoplastic

Congenital

2. Skin of the head and neck, mucosal and cranial nerves

Presenting on Rounds

Patient presentations should be goal directed and follow this format:

“Mr. Jones is a 63-year-old man with a T3 cancer of the tonsil that failed radiation. He initially presented with a two-month history of pain and a nonhealing ulcer on the left tonsil. He underwent six weeks of radiotherapy and was disease free for seven months. His tumor recurred, and three days ago, he underwent a mandibulotomy, neck dissection, hemiglossectomy and partial pharyngectomy with tracheostomy. A radial forearm free-tissue transfer was the reconstruction. He is afebrile (less than 38.5°C), and his perioperative antibiotics have been discontinued. He is tolerating his tube feeds at 100 cc per hour, and his drains have each put out 30 cc over the last 24 hours.”

The last sentence in your presentation should always start with “The plan is...” For example:

“The plan is to remove the drains today, continue the tube feedings, and start feeding the patient by mouth at one week post surgery. We also plan to cap his **tracheostomy** tube and remove it if he tolerates having it plugged. We have contacted social work in order to make sure that he has a place to go when we are ready to discharge him at day 8 or 9 post-op.”

For a general surgery patient, the presentation may be something like this:

“This is day 1 post colon resection for Mrs. Jones, a 60-year-old woman with colon cancer found on endoscopy obtained because of a positive test for occult blood in the stool.”

Discuss ins, outs, and drains. Once again, your last sentence should start with “The plan is...”

Always think of what you need to do to send the patient home. For example, if she still is not eating and needs IVs for fluid intake, the object would be to get her eating.

Postoperative Fevers

In surgery, the differential diagnosis, as it relates to specific symptoms, depends on the time since the procedure has been completed. For example, if a person has a fever, the most likely cause is dictated somewhat by the **postoperative day (POD)**. Remembering the **five Ws of post-op fever—Wind, Water, Walking, Wound, and Wonder drugs**—as a useful memory tool when you are following patients after surgery.

18

- **POD 1–2: Wind—Atelectasis (without air)** often causes a fever. Reasons include being on a ventilator, inadequate sighs during surgery, and (in the general surgery patient) incisional pain on deep breathing. This is treated with incentive **spirometry** because there is evidence that **deep inspiration** prevents atelectasis better than just coughing.
- **POD 3–5: Water—Urinary tract infections** are common during this timeframe. Foley catheters are sometimes still in place.
- **POD 4–6: Walking—Deep venous thrombosis** can occur. This is more of a problem in patients undergoing pelvic, orthopedic, or general surgery than in head and neck surgery. Subcutaneous, low-dose **heparin** and **venous compression devices** reduce the incidence of **thromboembolization**. Walking the patient on POD 1 is the best way to prevent this complication.
- **POD 5–7: Wound**—Most wound infections occur during this period. **Preoperative antibiotics** are important to prevent or reduce the risk of infection in head and neck surgery that crosses mucosal linings.
- **POD 7+: Wonder drugs**—Drugs can cause fevers. (Note that in obstetrics and gynecology, this W is “Womb,” and it precedes “Wonder drugs.”)

QUESTIONS

1. The five Ws of postoperative fever are: _____, _____, _____, _____, and _____.
2. A fever on postoperative day 5–7 may be due to an infection of the _____.
3. A fever on the night of surgery is most likely due to _____.

ANSWERS

1. Wind, water, walking, wound, wonder drugs
2. Wound
3. Atelectasis

ENT Emergencies

Airway

Airway emergencies are uncommon, but devastating when they do happen. Whether the patient lives or dies—or worse, lives for years in a coma—depends on the ability of those caring for him or her to **recognize, access, and manage** the airway. ENT physicians are experts in airway management, but often are not nearby when needed. The advanced trauma life support course you probably have taken or will take emphasizes management of airway emergencies. Predicting when difficulty will occur and being able to manage the difficult airway without it becoming an emergency is an even more valuable skill. Later, this chapter will list three types of airway difficulties that you might encounter.

A good rule of thumb about a **tracheotomy** is: If you think about performing one, you probably should. It is easier to revise a scar on the neck than to bring the dead back to life. If you are not an experienced surgeon and need an immediate surgical airway, then a **cricothyrotomy** is the preferred procedure. It is easier and less bloody than a tracheotomy. Please remember the airway is best found in the neck by **palpation**, not inspection. Take a moment and palpate your own **cricothyroid membrane**, immediately below your **thyroid cartilage**. To do an emergency **cricothyrotomy** you need only a knife. Feel the space, cut down and stick your finger in the hole, feel, and cut again, and again until you are in the airway. Do not worry about bleeding. Place an **endotracheal tube** in the hole (again, by feel). Be sure not to push it past the **carina**. By this time, you will be shaking like a leaf—it is okay to let someone else squeeze the bag. Pressure with a dressing will address most bleeding. Occasionally, you might need to use some sutures to stop the bleeding.

Choanal atresia is a congenital disorder in which the nasal choana is occluded by soft tissue, bone, or a combination of both. When unilateral, it presents with unilateral mucopurulent discharge. When bilateral, the neonate is unable to breathe. Since newborns are obligate nasal breathers,

establishing an airway is an acute otolaryngologic emergency. While this should be done in the operating room, a **Montgomery nipple** can be used as an interim measure prior to surgery.

Difficult Intubations

Anatomic characteristics of the upper airway, such as macroglossia or congenital micrognathia (e.g., Pierre Robin syndrome), can result in difficult laryngeal exposure. This syndrome is more commonly encountered in the young, muscular, overweight man with a short neck. Anesthesiologists are trained to recognize and manage the airway in these patients, but everyone caring for them must be aware of the potential difficulty. The need for a surgical airway in these patients often represents a failure of recognition and planning.

LUDWIG'S ANGINA AND DEEP NECK INFECTIONS

Ludwig's angina is an infection in the floor of the mouth that causes the tongue to be pushed up and back, eventually obstructing the patient's airway.

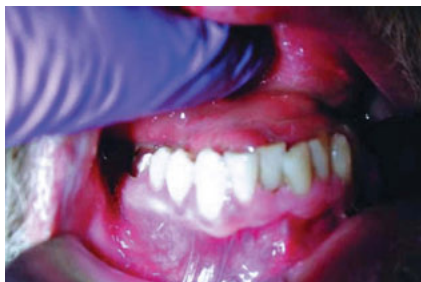

Figure 4.1.

This photograph depicts a gentleman with severe Ludwig's angina. Notice the swollen floor of the mouth and the arched, protruding tongue obstructing the airway.

Treatment requires **incision and drainage of the abscess**. The most common cause of this abscess is infection in the teeth. The mylohyoid line on the inner aspect of the body of the **mandible** descends **on a slant**, so that the tips of the roots of the **second and third molars** are behind and below this line. Therefore, if these teeth are abscessed, the pus will go into the **submandibular space** and may spread to the **parapharyngeal space**. Patients with these infections present with unilateral neck swelling, redness, pain, and fever. Usually, the infected tooth

is not painful. Treatment is incision and drainage over the submandibular swelling. Antibiotic coverage should include **oral cavity anaerobes**.

If, however, the tooth roots are above the mylohyoid line, as they are from the **first molar** forward, the infection will enter the **sublingual space**, above and in front of the mylohyoid. This infection will cause the tongue to be pushed up and back, as previously noted. These patients usually will require an awake-tracheotomy, as the infection can progress quite rapidly and produce airway obstruction. The firm tongue swelling prevents standard laryngeal exposure with a **laryngoscope blade**, so **intubation** should

not be attempted. Even if there is no airway obstruction on presentation, it may develop after you operate and drain the pus. This results from **post-operative** swelling, which can be worse than the swelling on initial presentation.

ACUTE SUPRAGLOTTIC SWELLING

Angioneurotic edema, either familial or due to a **functional or quantitative deficiency of C1-esterase inhibitor**, can also result in dramatic swelling of the tongue, pharyngeal tissues, and the supraglottic airway. Swelling can progress rapidly, and oral intubation may quickly become impossible, urgently requiring a surgical airway. Common medical treatments are IV steroids, and H1 and H2 histamine blockers.

PERITONSILLAR ABSCESS

This is a collection of purulence in the space between the tonsil and the pharyngeal constrictor. Typically, the patient will report an untreated sore throat for several days, which has now gotten worse on one side. The hallmark signs of peritonsillar abscess are fullness of the anterior tonsillar pillar, uvular deviation away from the side of the abscess, a “hot potato” voice, and, in some patients, trismus (difficulty opening the jaws). Treatment includes drainage or aspiration, adequate pain control, and antibiotics. Tonsillectomy may be indicated, depending on the patient’s history.

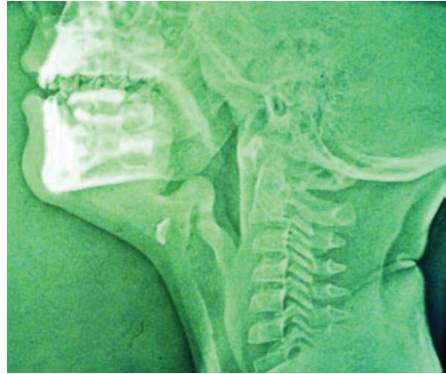

Figure 4.2.

Lateral neck, soft-tissue x-ray of a child with acute epiglottitis. Note the lack of definition of the epiglottis, often referred to as a “thumb sign” (see Chapter 18, Pediatric Otolaryngology). This can occur as a result of infections—**e.g., epiglottitis**, which was once common in children. Today, however, these infections are rare because of the widespread utilization of vaccination against *Haemophilus influenzae*. Epiglottic or supraglottic edema prevents swallowing. Early recognition of the constellation of noisy breathing, high fever, drooling, and the characteristic posture—sitting upright with the jaw thrust forward—may be lifesaving. Relaxation and an upright position keep the airway open. These children must not be examined until after the airway is secured.

Foreign Bodies

Foreign bodies can present as airway emergencies. Usually, however, by the time the patient gets to the emergency room, the foreign body in the airway has been expelled (often by the **Heimlich maneuver**), or else the patient is no longer able to be resuscitated. Foreign bodies in the **pharynx** or **laryngeal inlet** can often be extracted by **Magill forceps** after laryngeal exposure with a standard laryngoscope. The patient will usually vomit, so **suction is mandatory**.

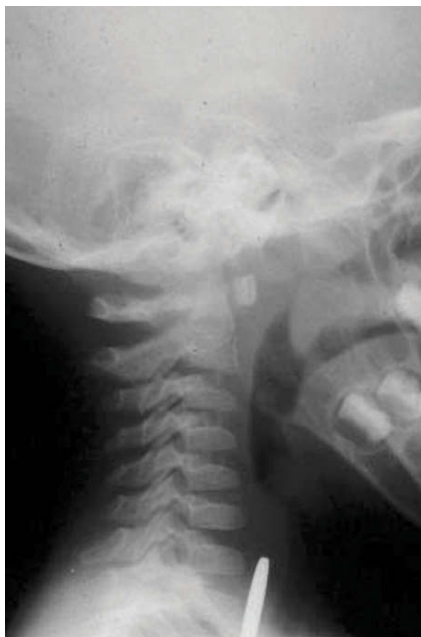

Figure 4.3.

A coin is seen here trapped in the patient's esophagus.

Bronchial foreign bodies will require operative **bronchoscopy** for removal. Occasionally, a tracheotomy will be required, such as for a patient who has aspirated a partial denture with imbedded hooks. Children often aspirate peanuts, small toys, etc., into their bronchi. Occasionally these patients present as airway emergencies, although they more typically present with **unexplained cough or pneumonia**. Chevalier Jackson, the famous **bronchoscopist**, has noted, "All that wheezes is not asthma." In other words, always remember to think of foreign body aspiration when a pedi-

atric patient presents with unexplained cough or pneumonia. If a **ball-valve obstruction** results, **hyperinflation of the obstructed lobe or segment** can occur. This is easier to visualize on **inspiration-expiration films**.

Mucormycosis

This is a **fungus infection** of the sinonasal cavity that occurs in **immuno-compromised** hosts. Typically it appears in patients receiving bone marrow transplantation or chemotherapy. It is a devastating disease, with a significant associated mortality. *Mucor* is a ubiquitous fungus that can become **invasive** in susceptible patients, classically those with diabetes with **poor glucose regulation** who became **acidotic**. If there is any other **system failure** (e.g., **renal failure**), mortality goes up significantly. The

fungus grows in the blood vessels, causing **thrombosis** and **distal ischemia** and, ultimately, tissue necrosis. This also leads to an **acidic environment** in which the fungus thrives.

The primary symptom is facial pain, and physical exam will show **black turbinates** due to **necrosis of the mucosa**. Diagnosis is made by **biopsy**. **Acutely branching nonseptate hyphae** are seen microscopically. Usually the infection starts in the sinuses, but rapidly spreads to the **nose, eye, and palate**, and up the **optic nerve** to the **brain**. Treatment is immediate correction of the **acidosis** and **metabolic stabilization**, to the point where **general anesthesia** will be safely tolerated (usually for patients in **diabetic ketoacidosis** who need several hours for rehydration, etc.). Then, wide **debridement** is necessary, usually consisting of a **medial maxillectomy** but often extending to a **radical maxillectomy** and **orbital exenteration** (removal of the eye and part of the hard palate) or even beyond.

Amphotericin B is the drug of choice. Many patients with mucormycosis also have renal failure, which precludes adequate dosing. Newer **lyosomal forms** of amphotericin B have been shown to salvage these patients by permitting higher doses of drugs. If the underlying immunologic problem cannot be arrested, survival is unlikely. In patients who are neutropenic, unless the white blood cell count improves, there is no chance for survival.

Sinus Thrombosis

See Chapter 9, Rhinology, Nasal Obstruction, and Sinusitis.

Epistaxis

Epistaxis is common and occurs in all people at some time. If the condition is severe or persistent, these people become patients. The most common bleed is from the anterior part of the septum. This area, called Kiesselbach's plexus, has many blood vessels. In

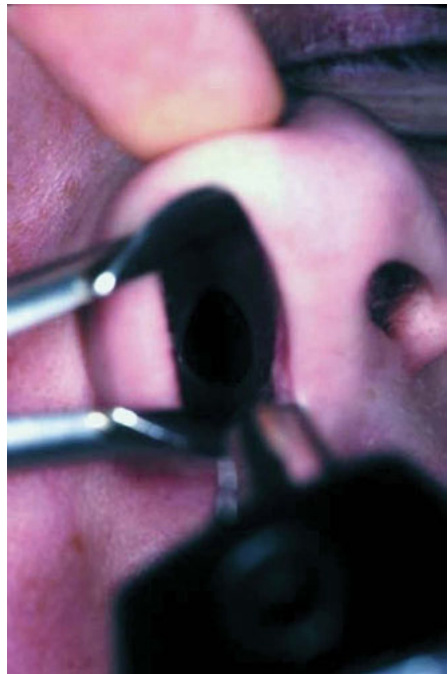

Figure 4.4.

Septal perforation may be secondary to trauma, cocaine (or even Afrin[®]) abuse, or prior surgery. Epistaxis commonly accompanies this condition and may be problematic.

children, these nosebleeds should be treated with oxymetazoline or phenylephrine nasal spray and digital pressure for 5–10 minutes. It is important for patients to look at the clock while applying the pressure; just 30 seconds can seem like an hour in such a situation, and the patient (or parent) may release the pressure too soon (which allows new blood to wash out the clot that was forming). The most common initiating event for these kinds of nosebleeds is digital trauma from a fingernail. Children's fingernails should be trimmed, and adults should be informed about avoiding digital trauma. Another consideration may be an occult bleeding disorder; therefore, adequate coagulation parameters should be studied if the patient continues to have problems. Cocaine abuse is a possible etiology in any patient and must be considered. A perforated nasal septum can be a warning sign.

Recurrent nosebleeds in a teenager can be especially problematic. Bleeding from the back of the nose in an adolescent male is considered to be a juvenile nasopharyngeal angiofibroma until proven otherwise. These patients frequently also have nasal obstruction. Diagnosis is made by physical examination with nasal endoscopy.

Some adult patients, often with hypertension and arthritis (for which they are taking aspirin), have frequent nosebleeds. When they present to the emergency room, they have a significant elevation of blood pressure, which is not helped by the excitement of seeing a brisk nosebleed. Treatment for these patients is topical vasoconstriction (oxymetazoline, phenylephrine), which almost always stops the bleeding. When the oxymetazoline-soaked pledgets are removed, a small red spot, which represents the source of the bleeding, can often be seen on the septum. Often, if such a bleeding source is seen, it can be cauterized with either electric cautery or chemical cauterization with silver nitrate. Nasal endoscopes permit identification of the bleeding site, even if it is not immediately seen on the anterior septum. These patients should also be treated with medication to lower their blood pressure. The diastolic pressure has to be reduced below 90 mm Hg. Many patients can then go home, using oxymetazoline for a few days. Furthermore, methycellulose coated with antibiotic ointment can be placed into the nose to prevent further trauma and allow the mucosal surfaces to heal. This is usually left in place for three to five days.

Sometimes the bleeding cannot be completely stopped, and packing is used as a pressure method of stopping the bleeding. If the bleeding is coming from the posterior aspect of the nose, then a posterior pack may need to be placed. An alternative is to place any one of various commercially

available balloons to stop the nosebleed. Patients who undergo anterior packing on one side may go home. However, if bilateral nasal packing is used or a posterior pack is placed, patients will need to be admitted to the hospital and carefully watched, because they can suffer from hypoventilation and oxygen desaturation. In general, the packing is left in place for three to five days and removed. During this time, prophylactic oral or parenteral antibiotics should be administered to decrease risk of infectious complications. If the patient re-bleeds, the packing should be replaced, and arterial ligation, endoscopic cauterization, or embolization can be considered. As always, these patients should be worked up for bleeding disorders. A patient with a severe nosebleed can develop hypovolemia, or significant anemia, if fluid is being replaced. These conditions necessitate increased cardiac output, which can lead to ischemia or infarction of the heart itself.

Necrotizing Otitis Externa

“Malignant” otitis externa is an old name for what should more appropriately be called necrotizing otitis externa. This is a severe infection of the external auditory canal, usually caused by *Pseudomonas* organisms. The infection spreads to the temporal bone and, as such, is really an osteomyelitis of the temporal bone. This can extend readily to the base of the skull and lead to fatal complications if it is not adequately treated. This disease occurs most commonly in older patients with diabetes, and can occur in AIDS patients. Any patient with otitis externa should be asked about the possibility of diabetes. It can be caused by traumatic instrumentation or irrigating wax from the ears of patients with diabetes. Patients with necrotizing otitis externa present with deep ear pain, temporal headaches, purulent drainage and granulation tissue at the area of the bony cartilaginous junction in the external auditory canal and facial nerve followed by other cranial neuropathies in severe cases.

To diagnose an actual infection in the bone (which is the *sine qua non* of this disease), a computed tomography (CT) scan of the bone, with bone windows, must be obtained. A technetium bone scan will also demonstrate a “hot spot,” but is too sensitive to discriminate between severe otitis externa and true osteomyelitis. The standard therapy is meticulous glucose control, aural hygiene, including frequent ear cleaning, systemic and topical antipseudomonal antibiotics, and hyperbaric oxygen in severe cases that do not respond to standard care. Quinolones are the drugs of choice because they are active against *Pseudomonas* organisms.

Complications of Acute Otitis Media

Meningitis, sigmoid sinus thrombosis, subperiosteal abscess of the mastoid, brain abscess, and facial nerve paralysis. See Chapter 5, Otitis Media.

Sudden Sensorineural Hearing Loss

Sudden sensorineural hearing loss (SSHL) is an idiopathic, unilateral, sensorineural hearing loss with onset over a period of less than 72 hours. The most common theories for the etiology are a viral infection or a disorder of inner ear circulation due to vascular disease. A wide variety of treatments have been used to treat SSHL, including oral and intratympanic steroids, hemodilutional agents, anticoagulants, antivirals, hyperbaric oxygen, and vitamins. The most common treatment for SSHL is a tapered course of oral corticosteroids and/or intratympanic corticosteroid injections, yet there is no clear-cut evidence that shows a significant treatment effect. Regardless, SSHL is a medical emergency that warrants urgent consultation and follow-up with an otolaryngologist. The prognosis is variable and depends on the patient's age, initial severity of the hearing loss, and promptness of medical treatment.

QUESTIONS

1. Abscessed teeth can rupture through the medial mandibular cortex into the sublingual space. This can cause the tongue to be pushed up and back. The biggest danger in this is loss of _____.
2. The easiest way to ensure that the airway isn't lost in this situation is to perform a _____.
3. Immunocompromised patients, especially patients with diabetes, can get a devastating fungal infection of the sinuses called _____.
4. Necrotizing otitis externa is a *Pseudomonas* infection of the _____ and _____, which can lead to fatal complications.
5. Often, _____ tissue is seen at the junction of the bony-cartilaginous junction in the external auditory canal in patients with necrotizing otitis externa.
6. The most common cause of a nosebleed in children is injury to vessels in _____.
7. A posterior nosebleed in an adolescent male is considered to be a _____ until proven otherwise.
8. Two topical vasoconstrictors often used in the nose are _____ and _____.

ANSWERS

1. Airway
2. Tracheotomy
3. Mucormycosis
4. Skull base or temporal bone
5. Granulation
6. Kiesselbach's plexus
7. Juvenile nasopharyngeal angiofibroma
8. Oxymetazoline, phenylephrine

Otitis Media

Otitis media may simply be defined as inflammation of the **middle ear space**—the space between the eardrum and the inner ear—due to any cause. It is the second most common disease diagnosed in young children. Otitis media can be classified by duration, patient symptoms, and physical exam findings. It is important for the clinician to be familiar with two common variants of otitis media: (1) **acute otitis media** and (2) **otitis media with effusion (OME)**.

Children with **acute otitis media** frequently present with sudden onset of fever, ear pain, and fussiness. In patients with acute otitis media, the eardrum is bulging and yellow or white in color with dilated vessels, and there is decreased movement of the eardrum on **pneumatic otoscopy** (insufflation of air into the ear canal).

Common bacteria that cause acute otitis media in children are *Streptococcus pneumoniae*, *Haemophilus influenzae*, and *Moraxella catarrhalis*. In healthy children older than two years of age who present with less severe symptoms, observation for 48 hours may be considered. If the decision is made to treat with antibacterial agents, **amoxicillin** dosed at 80 to 90 milligrams per kilogram per day is the **first-line antibiotic therapy**. Azithromycin can be used to treat patients who have a penicillin allergy.

The high incidence of resistant organisms can make the treatment of acute otitis media challenging. For example, in patients who do not respond to first-line antibiotic therapy, a **beta-lactamase-producing organism** or a resistant *Streptococcus* organism may be responsible for treatment failure. While treatment choices in such patients will be dictated by the prevalence

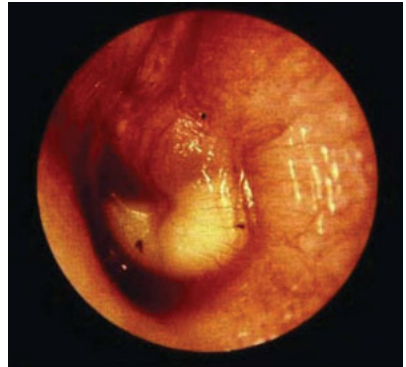


Figure 5.1.

This tympanic membrane demonstrates the bulging seen with an acute infection.

of resistant organisms in your community, a common second-line therapy for acute otitis media is high-dose amoxicillin-clavulanate.

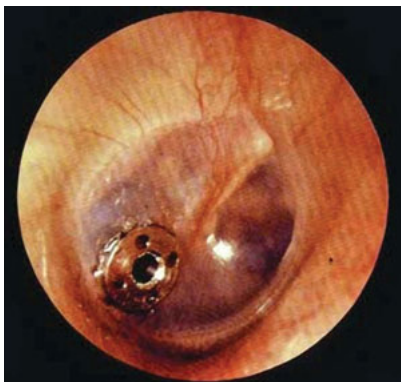


Figure 5.2.

Photograph of a tympanic membrane with a pressure equalizing (PE) tube in place. The tube permits aeration of the middle ear space.

Breastfeeding and vaccination with a pneumococcal conjugate preparation may decrease the incidence of acute otitis media in children, while other factors, such as daycare attendance, young siblings at home, and exposure to tobacco smoke, may predispose children to develop otitis media. Some children develop **recurrent acute otitis media**, or recurring acute, symptomatic ear infections. Such children may benefit from **pressure equalization (PE) tube, or ear tube, insertion** if they have three to four bouts of acute otitis media in six months or five to six bouts in a single year.

Insertion of PE tubes involves placing small tubes in the eardrum to ventilate the middle ear and prevent the negative pressure and fluid buildup. In a child with an open PE tube, ear drainage typically indicates an ear infection. An advantage of PE tubes is the ability to treat episodes of ear drainage with topical antibiotic therapy, such as fluoroquinolone otological drops applied to the ear canal. Currently, there is a trend to use fluoroquinolone drops rather than traditional neomycin/polymyxin B/hydrocortisone preparations, due to the theoretical risk of ototoxicity associated with these medications. The PE tubes generally extrude on their own after one to two years. In the past, antibiotic prophylaxis for a three- to six-month trial was an alternative treatment for children with recurrent acute otitis media. Due to concern over the development of resistant organisms, the routine use of antibiotic prophylaxis for recurrent acute otitis media in otherwise healthy children has been largely abandoned.

OME, or middle ear fluid without active infection, may occur after treatment of an acute episode of otitis media, or due to chronic eustachian tube dysfunction. While the majority of children will clear middle ear fluid within three months of an acute ear infection, those with eustachian tube dysfunction may have problems with persistent middle ear fluid. Children with OME are often asymptomatic, although they may complain of ear fullness or muffled hearing. These patients do not have the fevers, irritability, and ear pain that are associated with acute otitis media. On physical

examination, there may be an air-fluid level behind the eardrum and decreased mobility of the eardrum. Children with OME may have up to a **30- to 40-decibel (dB) conductive hearing loss, which in some studies affected speech development and learning.** Antibiotic therapy is not usually indicated for children with OME. Patients with OME are sometimes treated with a short course of oral or topical nasal steroids, to **decrease the swelling** in the eustachian tube and **allow ventilation of the middle ear space.** Referral to an otolaryngologist should be considered for children with at least three months of persistent middle ear effusion. Placement of PE tubes is often entertained for such children whose effusions are associated with hearing loss.

An **adenoidectomy**, or removal of the adenoid tissue in the nasopharynx, has been shown to reduce the need for PE tubes in children, presumably by removing a focus of eustachian tube inflammation. Adenoidectomy is often recommended if a child requires a second set of PE tubes, or with the first set of tubes if the child has significant nasal symptoms. Children usually grow out of the need for the tubes as they get older, as the eustachian tube assumes a longer and more downward-slanted course with time. However, there are certain subsets of patients, such as children with a history of cleft palate or trisomy 21, who can have long-term problems with otitis **media** and eustachian tube dysfunction.

OME in an adult, especially if it is **of recent origin and unilateral**, should prompt an examination of the nasopharynx for a disease process affecting the eustachian tube. **Early nasopharyngeal carcinoma** is well known for its silent nature—often the only sign is unilateral OME. Later in the disease process, the tumor **metastasizes** to the cervical lymph nodes and extends into the skull base, causing **cranial neuropathies.** In the past, nasopharyngeal examination was performed with mirrors, but most otolaryngologists now routinely use rigid or flexible endoscopic instrumentation.

Complications of Acute Otitis Media

Complications of acute otitis media were common in the pre-antibiotic era. It is largely because of those complications that otolaryngology developed as a specialty more than 100 years ago. With advances in the diagnosis and treatment of otitis media, such complications as **mastoiditis** and **meningitis** have decreased in incidence. However, **as the prevalence of resistant organisms increases**, especially *Streptococcus pneumoniae*, there is a chance that **these complications may again become more common.** Therefore, even if you never see a case during your medical school years, you must know about these complications and be able to recognize them if you encounter them in your practice. If untreated, acute otitis media can

lead to **several complications**, including **perforation of the eardrum, tympanosclerosis, mastoiditis, and meningitis**.

Purulent ear drainage in the setting of acute otitis media is likely due to eardrum, or tympanic membrane, perforation. The eardrum is the path of least resistance in the ear; thus, a build-up of middle ear purulence during an episode of acute otitis media can result in **spontaneous tympanic membrane (TM) rupture**. Treatment is similar to that described above for acute otitis media. Most commonly, the perforation will heal on its own within two weeks. However, persistent perforations may require surgical repair. Occasionally, eardrum perforations can be associated with chronic ear drainage, also known as **chronic suppurative otitis media**.

Another **residual effect** of acute otitis media and TM rupture is **tympanosclerosis**. Tympanosclerosis is the firm submucosal scarring that can appear as a chalky white patch on the eardrum. It can **infrequently lead to conductive hearing loss if the middle ear, and ossicles are involved extensively**.

Other more severe complications of otitis media include meningitis and mastoiditis. Meningitis originating from otitis media is believed to occur by **blood-borne spread** of the bacteria from the middle ear space into the **meninges**. Historically, the most common offending organism was *Haemophilus influenzae*, though epidemiologic patterns have been changing since the advent of the *Haemophilus influenzae* vaccine. Meningitis caused by otitis media is most often treated with intravenous antibiotics. A potential complication of pediatric meningitis is hearing loss.

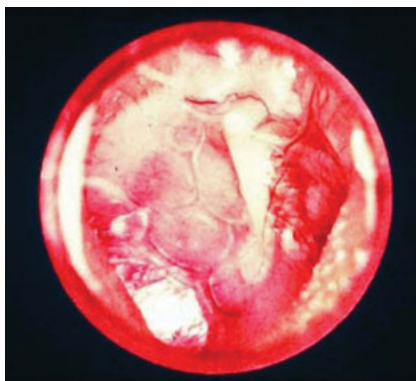


Figure 5.3.

Photograph of a tympanic membrane with chronic otitis media with effusion. Note the bubbles in the fluid behind the drum. While most effusions will resolve spontaneously, patients with persistent fluid may require tympanostomy tube placement.

Fluid collection in the air cells of the mastoid bone just behind the ear often occurs when acute otitis media is present. However, if **the fluid becomes infected and invades the bony structures, acute mastoiditis** develops. Patients with acute mastoiditis present with fever, **ear pain, and a protruding auricle**. Over the mastoid bone, the patient may have erythema of the skin, tenderness, and even a fluctuant mass.

A CT scan is a useful diagnostic tool if acute mastoiditis is suspected.

Intravenous antibiotics may initially be used to treat patients with acute mastoiditis. Surgery, including PE tube placement or mastoidectomy, may be necessary in patients who do not respond to medical therapy.

Other less common, but potentially devastating, complications of otitis media include epidural and brain abscesses, sigmoid sinus thrombosis, and facial nerve paralysis. A collection of pus can occur just outside the **dura** (termed an **epidural abscess**), or within the brain itself (a **brain abscess**), and surgical drainage is required. The

sigmoid sinus can become infected and thrombosed, and can serve as a **nidus of infection**. This classically leads to **showers of infected emboli**, causing “**picket fence fevers**.” **Facial nerve paralysis** in the setting of acute otitis media is believed to be caused by **inflammation** around the nerve, and thus generally responds to appropriate intravenous antibiotic therapy as well as drainage of the pus. This can be done via either a **myringotomy (an incision in the eardrum)** or, if necessary, a **mastoidectomy**.

Cholesteatoma

As mentioned above, some patients do not outgrow their eustachian tube dysfunction, and they go on to suffer from chronic negative middle ear pressure. This can result in **retraction** of the superior part of the ear drum, known as **pars flaccida**, back into the middle ear space. The outside of the eardrum is actually lined with **squamous epithelium**, which **desquamates** and produces keratin. Over time, the **keratinous debris** can get caught in the **pars flaccida retraction pocket**. This can continue to accumulate, expanding the pocket, and is then called a **cholesteatoma**, which often gets infected. Patients with cholesteatoma usually present with chronic ear drainage, often due to *Pseudomonas* or *Proteus bacteria*. These patients may be put on **ototopical antibiotic drops**, and their drainage may get better, only to return when the treatment is stopped. If the cholesteatoma is left untreated, it will **continue to grow and erode bony structures**. Possible sequelae include **hearing loss secondary to necrosis of the long process of the incus**; **erosion into the lateral semicircular canal**, causing dizziness; **subperiosteal abscess**; **facial nerve palsy**; meningitis; and brain abscess.

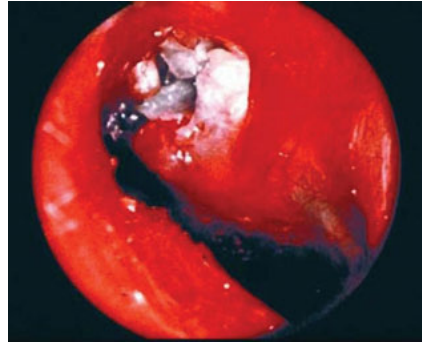


Figure 5.4.

Otoscopic view of left eardrum with cholesteatoma involving the *pars flaccida*. The white material is keratin filling the canal.

The treatment for cholesteatoma is surgical removal. While excision gets rid of the cholesteatoma, the underlying eustachian tube dysfunction is still present. Thus, cholesteatoma has the propensity to recur. Once patients have undergone surgery for removal of a cholesteatoma, they will need continuous monitoring of their ears for the rest of their lives.

Another way cholesteatoma can develop is when squamous epithelium migrates into the middle ear space through a hole in the eardrum. The perforation can come from a previous otitis media infection, a PE tube hole that did not heal, or trauma. **Marginal perforations, or holes along the outer portion of the eardrum**, are more likely to allow migration of epithelium than central perforations. Remember that the eardrum has **three layers: cuboidal epithelium in the middle ear, a fibrous layer in the middle, and squamous epithelium on the outside**. When there is a perforation, all three layers start to **proliferate**, but if the **squamous layer and the cuboidal layer meet**, the **fibrous layer will stop**. This can lead to a chronic perforation in which the middle ear is constantly being exposed to the outside, and thus develops a low-grade inflammation.

Clinical Example

A 14-year-old boy comes to your office complaining of painless right ear drainage. He is otherwise healthy, although he did have PE tubes in his ears as a child. On examination, you find he has slightly turbid drainage coming from a hole in his right eardrum. You diagnose chronic otitis media and learn that he does not know he has a perforation. He has not been trying to keep water out of his ear. You assume he has a *Pseudomonas aeruginosa* infection and prescribe ofloxacin otic solution (0.3%) twice a day for 10 days. He returns in two weeks with a dry ear and a small residual eardrum perforation. You next order an **audiogram**, a hearing test that shows a 15-dB **conductive hearing loss with normal discrimination** (ability to understand words). You tell the patient to keep water out of his ear. He comes back in four to six weeks and has not had any more drainage, so you refer him for a **tympanoplasty**.

Tympanoplasty

Tympanoplasty, an operation to **repair a hole in the eardrum**, is generally performed either **through the ear canal or from behind the ear**. The surgeon freshens up the edges of the hole. Then, because the fibrous tissue will not grow with squamous epithelium meeting cuboidal epithelium, a piece of **fascia temporalis** (the fibrous connective tissue overlying the temporalis muscle) or **tragal perichondrium** (the lining overlying the

tragus ear cartilage) is harvested as a **graft**. Small, semicircular cuts in the skin of the **external auditory canal (EAC)** are made about five millimeters (mm) out from the **annulus**, which is the outermost portion of the eardrum. The surgeon scrapes the skin off the bone and sneaks under the annulus to access the **medial aspect** of the eardrum and the middle ear space. The middle ear is then filled with a sponge-like material made of hydrolyzed collagen, which acts as a scaffold to hold the graft up against the medial aspect of the eardrum. Then the TM and skin are replaced and the EAC is packed with more sponge-like material. The collagen substance is eventually reabsorbed; meanwhile, the fibrous layer proliferates along the scaffolding of the graft to close the hole. The patient is usually instructed not to get water in the ear for three weeks. After this time, the surgeon will gently suction out any remaining collagen substance from the EAC.

As an example, a 49-year-old, non-diabetic male comes to your clinic with a draining right ear. He says it has drained off and on for years. Once again, the ENT exam is normal, except for copious purulence coming out of a TM perforation. You prescribe oral antibiotics and an antibiotic eardrop. You tell him to keep water out of his ear, which he does, and he comes back in two weeks, cleared up. You order an audiogram, which shows a 20-dB conductive hearing loss and good discrimination. He is then scheduled for a tympanoplasty in six weeks, but he comes in draining again in two weeks. He has not gotten his ear wet. You repeat medical therapy and, once again, he clears but drains a month later. He has a deep nidus of infection in his mastoid cavity that needs to be cleared. You schedule him for a CT scan, which shows no cholesteatoma, and then you perform a **tympanomastoidectomy**. At surgery, you find normal air cells throughout the mastoid cavity, with the exception of a few infected cells at the very tip of the mastoid. He does well post-op.

Now, say you have the same history and you could not see a cholesteatoma by physical exam, but the CT scan shows opacification of the middle ear space that is suspicious for cholesteatoma. The audiogram is the same. You perform the same operation (a tympanomastoidectomy) and remove the cholesteatoma. The patient does well post-op. Did you notice that when patients present with a recurrent draining ear, appropriate initial therapy includes systemic antibiotics as well as antibiotic-containing topical eardrops? This includes patients who have a previously placed PE tube. Patients with persistent otorrhea that does not respond to this initial therapy necessitate referral to an otolaryngologist for further evaluation.

CHAPTER 5

QUESTIONS

1. The most common organisms causing acute otitis media are _____, _____, and _____.
2. The first-line antibiotic therapy for acute otitis media in children is _____.
3. Children with persistent otitis media with effusion for ___ months and evidence of hearing loss are candidates for PE tube placement.
4. Ear drainage in patients with PE tubes in place should be treated with _____.
5. The presence of bilateral fluid in the ears may cause up to a _____ dB conductive hearing loss.
6. It is important to examine the _____ in any adult with unilateral otitis media with effusion.
7. In a patient with acute otitis media, in addition to being opaque and bulging, the eardrum has _____ mobility on pneumatic otoscopy.
8. The collection of trabeculated bony cavities lined with mucosa and connected with the middle ear is called the mastoid _____.
9. The *pars flaccida* of the eardrum can become _____ when there is chronic negative pressure in the middle ear.
10. The outside of the TM, including the *pars flaccida*, is lined with _____ epithelium.
11. _____ is suspected in a child presenting with fever, ear pain, a protruding auricle, and fluctuance behind the ear.
12. In patients with chronic eustachian tube dysfunction, desquamated debris, consisting mainly of keratin, collects in the retracted *pars flaccida*. Over time, this can grow and become a _____.
13. If a patient presents with a draining ear, appropriate therapy includes drops and _____.
14. If ear drainage persists despite medical therapy, the patient requires referral to an otolaryngologist to rule out _____.
15. _____ is the firm submucosal scarring that can appear as a chalky white patch on the eardrum.

ANSWERS

1. *S. pneumoniae, H. influenzae, M. catarrhalis*
2. Amoxicillin
3. Three
4. Otological fluoroquinolone drops
5. 30 to 40
6. Nasopharynx
7. Decreased
8. Air cells
9. Retracted
10. Squamous
11. Acute mastoiditis
12. Cholesteatoma
13. Oral antibiotics
14. Cholesteatoma
15. Tympanosclerosis

Hearing Loss

Hearing loss can be caused by a wide variety of factors. Patients may present with the complaint of being unable to hear, or they may complain of difficulty understanding. Often, a family member brings the patient for a hearing test because of communication difficulties. Older individuals often complain of **tinnitus**, which may be described as a sound like ringing, buzzing, or “crickets” in the ears. While tinnitus is usually a manifestation of hearing loss, it may have other causes as well. Hearing loss in children may be particularly difficult to detect, and is often confused with inattention or speech delay.

Depending on the specific type and etiology of the hearing loss, dramatically different treatments may be prescribed. It is important to determine whether the problem is with the **conductive pathway of the ear (conductive)** or with the **inner ear or eighth cranial nerve (sensorineural)**.

Conductive hearing loss can be due to **cerumen impaction**, swelling of the external auditory canal, tympanic membrane perforations, middle ear fluid, or **ossicular chain abnormalities**. **Sensorineural hearing loss** can occur as a result of injury to the hair cells in the **cochlea** or neural elements innervating the hair cells. The most common etiologic factors are persistent **noise exposure**, age-related changes of the eighth cranial nerve (**presbycusis**), **genetic factors**, and **infectious or postinflammatory processes**. Tumor growth (**acoustic neuroma**) along the course of the eighth cranial nerve can also be the etiology of sensorineural loss and must be included in the differential diagnosis.

Pure-tone audiometry (“the hearing test”) is frequently used to assess the patient’s hearing levels. The test requires that the patient is able and willing to cooperate. It can be especially difficult in the case of very young children. Hearing threshold levels are determined between 250 and 8000 **Hertz (Hz)** for pure tones and measured in decibels (dB). The 0-dB level is “normalized” to young, healthy adults and doesn’t mean there is absence of detectable sound. Some patients hear 0 dB, but reaching the threshold

CHAPTER 6

of hearing usually requires louder test signals. The higher the threshold is, the poorer the patient's hearing. Thresholds higher than 25 dB are considered abnormal.

During the **audiogram**, independent thresholds are determined for each ear for both **air conduction (conductive hearing)** and **bone conduction (sensorineural hearing)**. Air conduction measures the ability of the external and middle ear to transmit

sound to the cochlea. Conductive hearing loss can result from any barrier that could block sound transmission in this pathway (cerumen, perforation, middle ear fluid). This will create an **air-bone gap** between the air and bone conduction thresholds on the audiogram.

Sensorineural hearing loss can be diagnosed if the air conduction and bone conduction thresholds are equal but higher than 25 dB.

Our ability to hear is more complex than just listening to single pure tones in a sound-proof booth. Therefore, a test of the patient's ability to understand spoken words should be performed as well. In a speech discrimination test, the

patient is presented with phonetically balanced words (i.e., love, boat, pool, sell, raise) that are amplified to a comfortable hearing level as necessary. The results of this test, the speech discrimination score, should be between 90 percent and 100 percent for "normal" speech discrimination.

This test of clarity also assesses the function of the auditory division of the eighth cranial nerve. The ability to understand speech is very important, especially with respect to determining to what degree a hearing aid will help a particular patient. **Amplifying** garbled speech (with a hearing aid) has limited benefit for patients with very poor speech discrimination.

Tympanometry is commonly used to evaluate the tympanic membrane (TM) and middle ear status. This test assesses the mobility of the TM and its response to pressure changes in the external auditory canal. Three common patterns are shown in Figure 6.2. **Type A** plots arise when the external auditory canal is patent and the middle ear and TM are healthy (maxi-




Figure 6.1.

A conductive hearing loss in the left ear due to otitis media with effusion. Note that bone conduction thresholds are normal in both ears, but air conduction on the left is 30 dB poorer than that measured on the right. Remember that zero (0) dB does not refer to absence of sound, but rather represents an average threshold for young, healthy adults.

mum TM mobility when pressure in the canal is atmospheric). **Type B** plots occur when the middle ear is filled with fluid or the TM has a perforation (no peak in eardrum mobility). The two problems can be differentiated by examining the volume read by the impedance bridge. Middle ear fluid will generate normal volumes, while tympanic membrane perforations will generate large volumes. **Type C** plots (peak eardrum mobility when pressure is subatmospheric) are typical of patients with retracted TMs secondary to eustachian tube dysfunction. Tympanometry results can help detect middle ear fluid when the physical exam is unclear.

Conductive Hearing Loss

Careful physical examination of the ear with the aid of a microscope, tuning fork testing, and audiometric testing can frequently determine the cause of a conductive hearing loss. Most causes of conductive hearing loss can be medically or surgically corrected—they can be improved or resolved with treatment and without use of a hearing aid. Swelling of the external auditory canal secondary to **otitis externa** can be treated with appropriate topical medication. **Cerumen impaction** can be cleaned with irrigations, ear drops, or specialized instruments. **Middle ear fluid**, the most common cause of hearing loss in

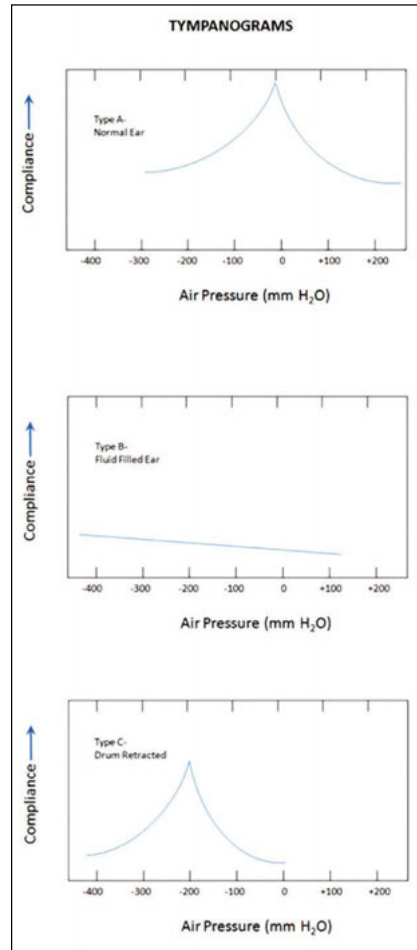


Figure 6.2.

Three tympanograms demonstrating change in compliance of the middle ear (vertical axis) with changes in ear canal pressure. Type A is normal, with the greatest compliance at the point where the pressure in the ear canal is equal to that of atmospheric pressure (peak is at 0). Type B demonstrates very poor compliance at any frequency, suggestive of a tympanic membrane (TM) immobilized by fluid in the middle ear or a TM perforation (no peak). Type C represents a tympanogram in which the compliance of the membrane is greatest at a point where the pressure in the canal is 200 mm of water below that of atmospheric pressure (peak shifted to the left). This suggests inefficient eustachian tube function with persistent negative pressure in the middle ear.

children, can be treated with antibiotic therapy or myringotomy tubes, and **tympanic membrane perforations** can be surgically repaired.

Cholesteatoma often presents with hearing loss, and in the physical examination, it can be confused with cerumen.

Conductive hearing loss present on the audiogram but not readily apparent on the physical exam suggests problems with the ossicular chain. One common disease process affecting the ossicular chain is **otosclerosis**, a hereditary disease process that involves bony proliferation within the temporal bone. These bony changes commonly occur at the footplate region of the **stapes**, causing gradual fixation of the ossicular chain. This fixation, in turn, **decreases the mobility** of the stapes footplate and creates a conductive hearing loss. Surgical correction— **stapedotomy**—is available. A stapedotomy procedure re-establishes **ossicular continuity** by removing the fixed stapes ossicle and placing a prosthesis between the **incus** and the **vestibule of the inner ear**. Sound vibrations can then be transmitted from the ossicular chain, through the prostheses and into the inner ear, restoring the patient's hearing.

Sensorineural Hearing Loss

Sensorineural hearing loss (SNHL) is the most common form of hearing loss. It is generally not treatable with surgery, although cochlear implants and other implantable audiologic devices may be helpful in cases of profound sensorineural or mixed hearing loss. There are many causes of this type of hearing loss, but age-related changes to the cochlea causing **presbycusis** are by far the most frequent cause. As we age, the outer hair cells within the cochlea gradually deteriorate, causing a **symmetrical SNHL** that begins in the high frequencies (Figure 6.2). Patients with presbycusis may also complain of tinnitus and have difficulty with speech discrimination.

Another common type of hearing loss is secondary to **acoustic trauma** or “**noise exposure.**” Noise exposure is common in certain industries and is closely regulated by a federal government agency, the Occupational Health and Safety Administration. Recreational target shooting, hunting with firearms, use of personal stereos or iPods® or other MP3 devices with headphones, loud music exposure, power tools, etc., can cause a specific type of hearing loss with a characteristic audiometric pattern (Figure 6.3). Patients suffering from noise-induced hearing loss have a symmetric “noise notch” in bone-conduction thresholds at approximately 4000 Hz. Prevention is vital, and counseling should be part of routine health maintenance. Treatment consists of hearing education, noise avoidance when possible, and appropriate hearing protection with ear plugs or ear muffs when loud

noise is present. Patients should also have regularly scheduled audiometric follow-up.

Sudden sensorineural hearing loss is an acute loss of hearing that represents an ENT emergency and deserves special management. Please refer to Chapter 4, ENT Emergencies, for further discussion of this problem.

Patients with **asymmetric** SNHL require a more thorough evaluation to rule out a benign tumor of the eighth cranial nerve, known as an **acoustic neuroma**. Although most patients with an asymmetric hearing

loss do not have an acoustic neuroma, hearing loss is by far the most common presenting complaint in patients with such tumors. In addition, these patients will frequently have very poor speech discrimination scores and tinnitus in the affected ear. They may also occasionally have disequilibrium complaints, although true **vertigo** is rare. Specialized audiometric testing can be done to assist in the diagnosis of acoustic neuromas, but magnetic resonance imaging (MRI) with gadolinium is the diagnostic test of choice. Physical exam and testing may elucidate an easily treatable cause of hearing loss. However, more serious causes can be present that require careful assessment and complex management. To ensure that diagnoses of serious conditions such as cholesteatoma or acoustic neuroma are made, patients with hearing loss should be referred to an otolaryngologist for evaluation and management of their care. For this reason, many states require an evaluation by a physician before a hearing aid can be fitted.

Hearing aids are effective in rehabilitation of hearing loss in most patients. Aids vary widely in their power (gain), frequency response, size, and cost. Optimal fitting requires a professional knowledgeable in the nuances of amplification technology. Even for some patients with total SNHL, a **cochlear implant** can provide direct stimulation of the cochlear nerve and can be very helpful. Currently, patients with bilateral profound

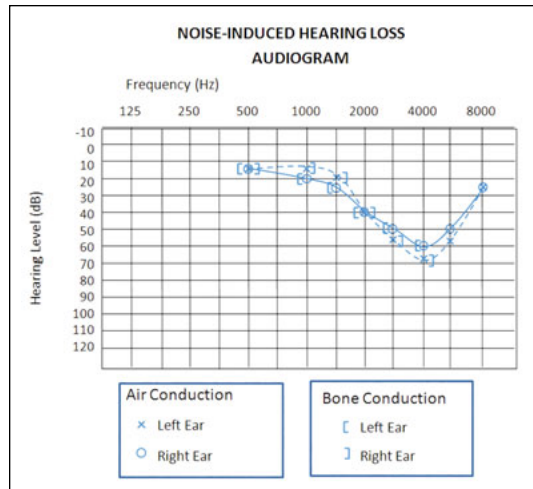
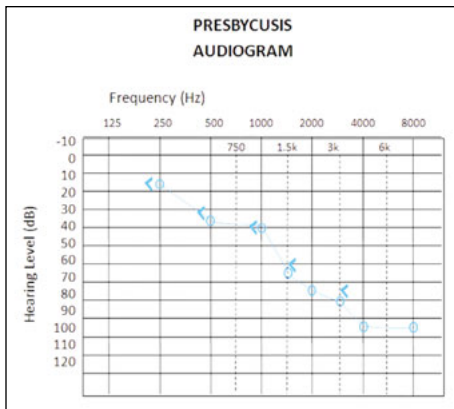


Figure 6.3.

This audiogram suggests noise exposure that may be encountered occasionally in younger individuals who have been exposed to hazardous or “toxic” noise. Note the high-frequency dip, with a maximum loss at 4000 Hz.

CHAPTER 6



46

Figure 6.4.

Audiogram of a patient with presbycusis. Note that low-tone thresholds are relatively normal, with a drop in thresholds at higher frequencies. This is a consequence of the normal aging process and may vary widely from patient to patient.

hearing loss are candidates. Younger children are implant candidates as well. This has proven extremely helpful in their language and social development. All newborns should undergo hearing screening, so that appropriate measures may be taken as soon as possible.

QUESTIONS

1. The most common cause of a conductive hearing loss in children is _____.
2. The magnitude of a hearing loss is documented in the _____.
3. The two major types of hearing loss are _____ and _____.
4. Conductive hearing loss is present when there is a difference between _____ and _____ conduction thresholds.
5. Sensorineural hearing loss is present when air and bone conduction thresholds are _____ but show a hearing loss.
6. Noise-induced hearing loss often produces a high-frequency _____ in the audiogram.
7. Otitis media with effusion produces a _____ tympanogram.
8. Presbycusis produces a hearing loss that slopes to the _____ side of the audiogram.
9. A patient with an asymmetric sensorineural hearing loss must be evaluated for the potential of having an _____.

ANSWERS

1. Fluid in the middle ear (otitis media with effusion)
2. Audiogram
3. Conductive, sensorineural
4. Air, bone
5. Approximate, similar
6. Notch
7. Type B (flat)
8. Downward, right
9. Acoustic neuroma

Dizziness

People often come to the otolaryngologist with a complaint of “dizziness,” including symptoms such as **disequilibrium**, **syncope**, **lightheadedness**, **ataxia**, and **vertigo**. As otolaryngologists, we focus on disease processes that produce true vertigo (an illusion of motion), which is primarily associated with the balance organs of the inner ear. These are referred to as **peripheral** vestibular disorders. When **central** vestibular disorders are considered, the differential diagnosis for dizziness becomes quite broad. Therefore, if your patient does not complain of the true illusion of motion, redirect your questioning to the evaluation of syncope or **episodic hypotension**. You may also want to consider imaging studies of the brain to rule out neoplasm, demyelinating disease, or a vascular abnormality. These patients may also need referral to a neurologist or cardiologist.

Vestibular Testing

Vestibular testing can be performed to help determine whether the problem exists within the vestibular (balance) portion of the inner ear. Vestibular testing may include an audiogram, electronystagmography (ENG), rotational chair test, posturography, and electrocochleography (ECOG), depending on the clinical situation.

There are four main parts to **ENG testing**: the calibration test, which measures rapid eye movements; the tracking test, which evaluates the ability of the eyes to track a moving target; the positional test, which measures responses due to head movements; and the caloric test, which measures responses to warm and cold water introduced to the ear canal. ENG is the “gold standard” for detecting unilateral peripheral vestibular disorders.

Rotatory chair testing is the “gold standard” for diagnosing bilateral vestibular weakness. The patient is slowly spun in a rotating chair and dizziness is measured with optokinetic testing and a fixation test. Moving platform **posturography** is a method of quantifying balance, but should not be used alone to diagnose vestibular disorders. It is most useful in quantifying balance improvement (or worsening) following treatment for a

particular problem, and can help identify the functional dizzy patient. ECOG is not really a test of the vestibular system, but is a useful test of hearing in the evaluation of Ménière's disease. The test is a variant of brainstem audio-evoked response and, if possible, should be performed during active Ménière's attacks.

Benign Paroxysmal Positional Vertigo

One of the most common causes of vertigo seen by otolaryngologists is benign paroxysmal positional vertigo (BPPV). This disorder is caused by sediment, such as **otoconia (calcium carbonate crystals)** that have become free floating within the inner ear. When the patient turns his or her head quickly or into a certain position, this free-floating material moves the balance canal fluid (**endolymph**) in the inner ear and stimulates the vestibular division of the eighth cranial nerve. This motion creates an intense feeling of vertigo that lasts less than 60 seconds and passes when the material settles. Patients are usually able to describe the precise motion that precipitates this intense, brief episode of vertigo. Rolling over in bed is a movement that frequently initiates an episode and is a fairly specific symptom. The name of the syndrome comes from the intense, episodic (paroxysmal) vertigo initiated by certain head positions (positional) that is not related to a **central nervous system (CNS)** tumor (benign). This disorder can occur without any specific inciting event, but is often seen after significant head trauma or an episode of vestibular neuronitis.

BPPV can usually be successfully treated with a canolith reposition maneuver (Epley or Semont maneuver) in the office setting. Dislodged, free-floating otoliths repositioned into the vestibule (a portion of the inner ear) is about 80 percent effective in eliminating symptoms of BPPV. After a period of time, symptoms may recur, requiring retreatment. Retreatment is equally effective in relieving symptoms. Medical therapy with vestibular suppressants is ineffective because the episodes of vertigo are so fleeting, and should be discouraged. Brandt-Daroff exercises are a home method of treating BPPV. They can be effective, but may take more time to be effective.

Surgical treatments, such as transtympanic gentamycin injections, posterior semicircular canal plugging, vestibular nerve sectioning, sacculotomy, and labyrinthectomy, are some of the surgical options reserved for severe intractable cases of BPPV. However, they are very rarely employed, as they can be associated with significant risk of hearing loss and other complications.

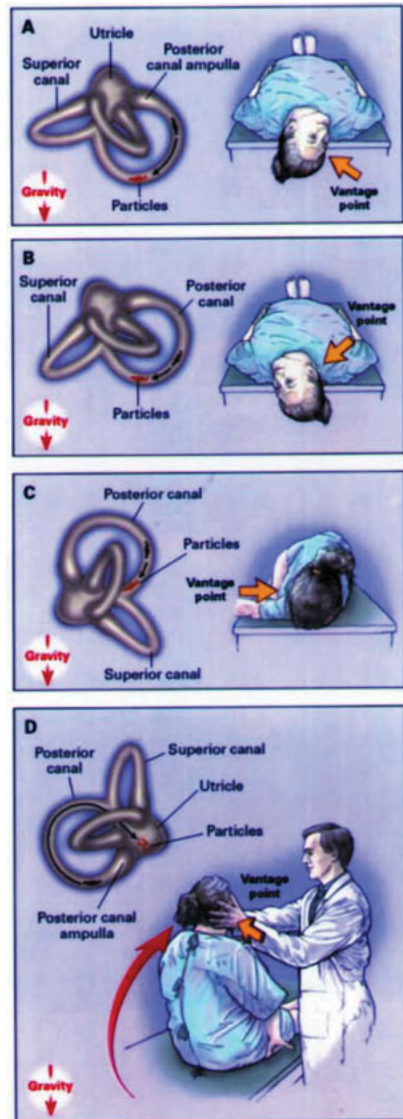
Figure 7.1.

Bedside maneuver for the treatment of a patient with benign paroxysmal positional vertigo (BPPV) affecting the right posterior semicircular canal. The presumed position of the debris within the labyrinth during the maneuver is shown in panels A–D. The maneuver is a three-step procedure. The Dix-Hallpike test is performed with the patient's head rotated 45° toward the right ear, and the neck slightly extended with the chin pointed slightly upward. This position results in the patient's head hanging to the right (panel A). Once the vertigo and the nystagmus provoked by the Dix-Hallpike test cease, the patient's head is rotated about the rostral-caudal body axis until the left ear is down (panel B). Then the head and body are further rotated until the head is face down (panel C). The vertex of the head is kept tilted downward throughout the rotation. The maneuver usually provokes brief vertigo. The patient should be kept in the final, facedown position for about 10–15 seconds. With the head kept turned toward the left shoulder, the patient is brought into the seated position (panel D). Once the patient is upright, the head is tilted so that the chin is pointed slightly downward. Used with permission, Furman et al., *NEJM* 1999; 341(21):1590-1596. Copyright ©1999, Massachusetts Medical Society, All Rights Reserved.

Vestibular Neuronitis

Another common cause of vertigo is **vestibular neuronitis** or **labyrinthitis**. It is thought to be caused by inflammation, secondary to a viral infection, of the **vestibular portion of the eighth cranial nerve** or of the inner ear balance organs (**vestibular labyrinth**). It is frequently associated with recent flu symptoms (upper respiratory infection). The patient will usually awaken

with room-spinning vertigo that will gradually become less intense over 24–48 hours. During this period, the patient's hearing is generally unchanged, and nausea with or without emesis is common. Treatment is symptomatic, including **vestibular suppressant medications**, antiemetic medications, and a short, tapering course of oral steroids. It may take several weeks for the symptoms to completely resolve. **Residual**



vestibulopathy that persists for months or even years is not uncommon, and is best managed with vestibular rehabilitation.

Ménière's Disease

Ménière's disease is usually diagnosed by history when patients have a particular symptom complex. Patients develop intense, episodic vertigo, usually lasting from 30 minutes to four hours, and associated with fluctuating hearing loss, roaring tinnitus, and the sensation of aural fullness. Even after the episode is over, some hearing loss often remains. (Remember that in BPPV, the vertigo lasts less than one minute, and in vestibular neuronitis, the vertigo lasts 24–48 hours.) Although the precise cause of Ménière's disease has not been unequivocally determined, the symptoms are believed to be secondary to a distention of the **endolymphatic** space within the balance organs of the inner ear.

The disease can be very difficult to treat because its course is very unpredictable. Patients can suffer from frequent attacks and then abruptly stop having symptoms, only to resume attacks years later. Treatment strategies have been focused on decreasing the endolymphatic fluid pressure within the vestibular portion of the inner ear. Salt restriction and thiazide diuretics are frequently used as first-line agents. If this does not adequately control the patient's symptoms, additional intervention can be used. **Vestibular ablation by instillation of ototoxic medication** (i.e., gentamicin) into the middle ear for absorption through the round window membrane and into the inner ear has also been used with success, and has a low incidence of hearing loss.

Surgical options for incapacitated patients include **endolymphatic sac decompression into the mastoid cavity**, vestibular nerve section, and **labyrinthectomy**. Vestibular nerve section is an intracranial procedure that involves transecting the vestibular portion of the eighth cranial nerve near the brainstem. This procedure disrupts the aberrant vestibular signals from the affected ear, while preserving the patient's current hearing thresholds. Labyrinthectomy disrupts the aberrant vestibular signals without the risks associated with an intracranial procedure, but it destroys any hearing in the operated ear. Because of this, labyrinthectomy is considered only if the patient's hearing has declined to the point of not being useful, usually after having Ménière's disease for an extended length of time. Treatment of patients with Ménière's disease must be managed in a stepwise fashion, with careful consideration given to the patient's intensity of symptoms and frequency of attacks, as well as how the disease is affecting his or her life and overall general health. Medical and surgical treatments are effective and are preferable to disability.

QUESTIONS

1. Dizziness associated with an illusion of motion is termed _____.
2. Sudden vertigo that develops without ear symptoms and lasts for 24–48 hours is most likely _____.
3. BPPV or _____ is vertigo precipitated by positional changes, lasting 10–60 seconds, and unassociated with serious illness.

ANSWERS

1. Vertigo
2. Vestibular neuronitis or labyrinthitis
3. Benign paroxysmal positional vertigo

Facial Nerve Paralysis

Facial paralysis is a devastating condition for the patient and his or her family. It may occur spontaneously, following trauma or surgical procedure, or as a result of malignant tumors of the pinna, the parotid gland, or the skull base. Paralysis involving all divisions of the nerve is **peripheral**, and that sparing the forehead is **central**. Facial paralysis is usually graded on a scale of 1 to 6, where 1 is normal and 6 is a flaccid complete paralysis.

Bell's Palsy

Bell's palsy is a unilateral facial nerve paralysis that is, by definition, **idiopathic**. You must be careful to rule out other potential causes of facial paralysis before making this diagnosis. **Polymerase chain reaction** studies have demonstrated herpetic infection in a majority of cases. Therefore, a better term might be viral or herpetic facial paralysis.

The clinical course of Bell's palsy is quite characteristic. The onset is usually sudden, with the patient often noticing the symptoms upon waking from sleep. The recovery is gradual, but spontaneous recovery can be expected in more than 85 percent of the cases. Medical therapy (within three days) with oral steroids (60 mg of prednisone daily) and antiviral medication has been shown to increase the frequency of complete recovery. Carefully recording their history is important when treating these patients. **Gradual onset** of symptoms (over months), paralysis that does not begin to recover by six to eight weeks, or **recurrent** symptoms on the same side suggest tumor and should be further **evaluated** by gadolinium-enhanced MRI. Studies have shown that up to 30 percent of patients diagnosed with

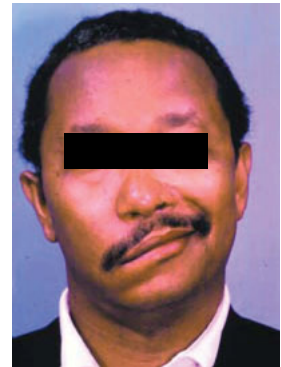

Figure 8.1.

This patient has suffered paralysis of the right facial nerve; hence, the asymmetry when he attempts to smile. Facial nerve paralysis involves both the upper and lower divisions of the facial nerve. A lesion of the supranuclear tracts would spare the forehead and represent a “central seventh.”

idiopathic Bell's palsy were found to have another cause for their facial paralysis, such as a facial nerve neuroma, parotid gland malignancy, or **cerebello-pontine angle tumor**.

Ramsay-Hunt's Syndrome

Another syndrome that includes facial nerve paralysis is Ramsay-Hunt's or **herpes zoster oticus**. In this case, facial nerve paralysis is accompanied by severe pain and a vesicular eruption in the external auditory canal and auricle in the distribution of the facial nerve. The vesicular lesions generally, but not always, precede the facial nerve paralysis. Vesicles may be nonpainful and quite small (even undetectable). The prognosis for recovery is significantly poorer than that of Bell's palsy. Medical therapy with antiviral agents and oral steroids is now considered standard and should be instituted early in the course of the disorder.

Temporal Bone Fractures

The facial nerve has an elongated course throughout the temporal bone. Significant head trauma can produce fracture lines through the temporal bone that may affect the facial nerve in one of two ways. The fracture line can directly traverse the facial nerve and transect it or cause a bony fragment to directly impale the nerve, or the fracture line may be some distance away from the nerve and still cause stretching or bruising of the nerve. This second situation creates edema and swelling of the nerve and its surrounding sheath, which can impede axoplasmic flow and create a conduction block. If the facial nerve has not been completely transected, the swelling and subsequent facial nerve paralysis can take up to 72 hours to develop. Therefore, careful assessment of the facial nerve **at initial presentation** is important in later management decisions.

Unfortunately, a temporal bone fracture is usually the result of significant head trauma, and the patient may have multiple other injuries that render him or her unconscious and unable to perform voluntary facial motion. Also, medical teams may be performing lifesaving intervention, so facial nerve assessment may not be an immediate priority. If the status of the facial nerve is in question, specialized electrical testing and high-resolution CT scanning of the temporal bone can be done to assess the facial nerve along its intratemporal course. If the nerve appears to be impaled by a bony spicule, facial nerve exploration via a transmastoid and/or intracranial approach should be performed. Facial nerve transection can be repaired with either direct **reanastomosis** or, if this procedure would cause undue tension, an **interposition graft (greater auricular or sural nerve)**. Most

facial nerve injuries related to trauma involve contusion injuries that can be followed expectantly and tend to do well over the long term.

Temporal bone trauma can also affect a patient's hearing. A complete sensorineural hearing loss is frequently seen if the fracture line disrupts the cochlea or balance organs. However, if the fracture involves the middle ear or ear canal, conductive hearing loss may occur secondary to a middle ear blood collection (**hemotympanum**), fractures of the ossicular chain creating a discontinuity, or a TM perforation. Hearing assessment and subsequent treatment can be done after more serious acute injuries have been stabilized.

Eye Care in Facial Paralysis

The facial nerve provides a critical function to the eye—namely, eyelid closure. This action provides a valuable protective function of maintaining moisture to the **cornea** over the external surface. The eyelid blink sweeps tears over the cornea, and eyelid closure at night prevents the cornea from drying. Without this protection, the cornea can become progressively more dry, causing significant pain, **corneal ulceration**, scarring, and ultimately permanent changes in vision. In addition, the eyelid blink reflex protects the eye by preventing foreign bodies from contacting the surface and damaging the cornea. Patients with facial nerve paralysis need to use artificial tears frequently during the day, a lubricant at night while they sleep, and in some cases, a wearable clear plastic moisture chamber for protection and humidification. Prevention, by early use of these therapies, is the best treatment for corneal injuries. Surgical rehabilitation is possible with placement of a gold weight into the upper eyelid. This allows gravity to pull the eyelid down, resulting in an almost natural appearance and improved function.

Facial plastic surgeons are otolaryngologists with specialized training in techniques to improve the appearance and function for patients with facial nerve disorders. A detailed discussion of reinnervation and reanimation procedures is beyond the scope of this book, but the reader is referred to Chapter 13, Facial Plastic Surgery, for other more common procedures performed in facial plastic surgery.

CHAPTER 8

QUESTIONS

1. Peripheral facial paralysis can be due to _____, _____, or _____.
2. Facial paralysis without an identified etiology is termed _____.
3. Bell's palsy is commonly due to _____ and should be treated with _____ and _____.

ANSWERS

1. Tumors of parotid or skull base, infections, trauma
2. Bell's palsy
3. Viral or herpetic infection, steroids, antivirals

Rhinology, Nasal Obstruction, and Sinusitis

Patients present to primary care providers with a variety of nasal complaints, ranging from rhinorrhea and postnasal drainage to obstruction and pain. **Rhinorrhea** and **postnasal drainage** can result from allergic rhinitis, nonallergic rhinitis, vasomotor rhinitis, and acute and chronic rhinosinusitis. **Nasal obstruction** can be caused by anatomic deformities (including **septal and external nasal deviation**, **nasal valve compromise**, **turbinate hypertrophy**, nasal **polyps**) and inflammatory changes resulting in **mucosal edema**. Successful treatment of the varying causes of rhinorrhea and obstruction is based on an accurate diagnosis of the underlying cause.

Vasomotor rhinitis and **nonallergic rhinitis** can mimic allergic rhinitis. In both cases, patients present with clear rhinorrhea, no other allergic symptoms or history, and allergy tests are negative. Vasomotor rhinitis is often triggered by food, temperature change, or sudden bright light. Intranasal steroid sprays are the best treatment for nonallergic and vasomotor rhinitis.

The “Common Cold”

Acute viral rhinosinusitis is frequently attributed to one of a multitude of rhinoviruses, and results in symptoms we refer to as the “common cold.” The pathophysiology involves infection, inflammation, mucosal swelling, and increased mucus production. Low-grade fever, facial discomfort, and purulent nasal drainage are also common symptoms. Treatment is symptomatic, with antipyretics, hydration, analgesics, and decongestants recommended, as needed. Spontaneous resolution occurs in 7–10 days. Antibiotic treatment of the common cold is discouraged, but unfortunately, patients often request (or demand) antibiotics early in the course of viral illness. When spontaneous recovery occurs, they assume that the antibiotics were responsible. This is a major cause of excessive antibiotic use and has contributed to the surge in antibiotic resistance.

Acute Bacterial Rhinosinusitis

Prolonged mucosal edema, from whatever etiology causes sinus obstruction and retention of secretions, may lead to **acute bacterial rhinosinusitis**. Patients may exhibit several of the *major symptoms* (facial pressure/pain, facial congestion/fullness, purulent nasal discharge, nasal obstruction, anosmia) and one or more of the *minor symptoms* (headache, fever, fatigue, cough, toothache, halitosis, ear fullness/pressure). **Radiographic studies** (plain films or CT scans) do not differentiate acute bacterial rhinosinusitis from a viral upper respiratory infection (URI). More than 80 percent of patients with a viral URI also have an abnormal sinus CT scan. Time will usually differentiate a bacterial from a viral infection. It usually takes 7–10 days for a viral infection to resolve. Symptoms lasting beyond 7–10 days, or worsening after 5 days, suggest that bacterial infection is being established. The organisms responsible are similar to the organisms that cause acute otitis media and include *Streptococcus pneumoniae*, *Haemophilus influenzae*, and *Moraxella catarrhalis*. By definition, acute rhinosinusitis persists less than one month, and **subacute rhinosinusitis** lasts more than one month but less than three months. **Chronic sinusitis** is defined by symptoms that persist more than three months, and usually has a different underlying microbiology with increased numbers of anaerobic organisms.

The treatment of choice for acute rhinosinusitis (as well as acute otitis media) has been a 10-day course of either amoxicillin or trimethoprim/sulfamethoxazole. Resistance to amoxicillin has prompted some physicians to consider using amoxicillin/clavulanate or a second-generation cephalosporin or macrolide or a quinolone instead of amoxicillin as the first-line therapy. More recently, the appearance of penicillin resistance in *S. pneumoniae* infection (which has a different resistance mechanism than beta-lactamase production) has resulted in the recommendation that higher doses of amoxicillin be used routinely. Drugs that do not adequately cover *H. influenzae* are inappropriate treatment for either otitis media or rhinosinusitis. **Adjunctive**

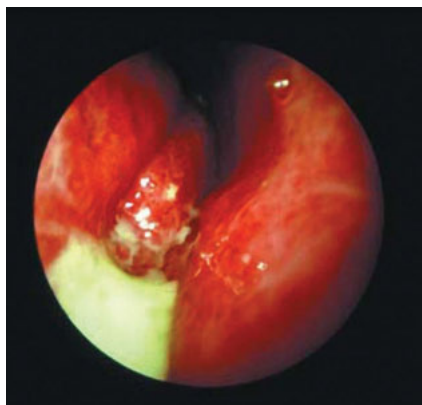

Figure 9.1.

Acute rhinosinusitis. Note purulent drainage extending from the middle meatus over the inferior turbinate. Symptoms persisting longer than 7–10 days suggest bacterial infection, and antibiotic therapy is indicated.

measures may include topical decongestants (oxymetazoline) for three days, mucolytics (guaifenesin), and oral decongestants. Severe or recurrent cases may require systemic steroids. Antihistamines and topical steroids are not usually indicated, unless allergy is also a major concern. Patients with sinusitis should be **referred** to an otolaryngologist if they have **three to four infections per year, an infection that does not respond to two three-week courses of antibiotics, nasal polyps on exam, or any complications of sinusitis.**

Several types of acute sinusitis merit further mention. Acute frontal, ethmoid, and sphenoid sinusitis that are not appropriately treated or do not respond to therapy can have serious consequences.

Frontal Sinusitis

The frontal sinus lining has veins that penetrate the posterior sinus wall and go directly to the dura on the opposite side. These veins can quite easily **transmit organisms** or become **pathways for propagation of an infected clot**. This can quickly lead to meningitis and even brain abscess. In fact, the most common cause of frontal lobe abscess is frontal sinusitis.

Therefore, the diagnosis of acute frontal sinusitis with an **air-fluid level** requires **aggressive** antibiotic therapy. The key to frontal sinusitis is to cover *S. pneumoniae* and *H. influenzae*, as well as get good cerebrospinal fluid penetration. Pain is severe, and patients usually require hospital admission for treatment and close observation. **Topical vasoconstriction** to shrink the swollen mucosa around the nasofrontal duct and restore natural drainage into the nose should begin in the clinic and continue throughout the hospital stay. Systemic steroids may also be considered to decrease swelling. If frontal sinusitis does not greatly improve within 24 hours, the frontal sinus should be surgically drained to prevent serious **intracranial infections.**

Ethmoid Sinusitis

Severe ethmoid sinusitis can result in **orbital cellulitis** or abscess. These patients present with **eyelid swelling, proptosis, and double vision**. While one might assume the double vision is due to the involvement of the nerves of the cavernous sinus, it can also be caused by an abscess located in the orbit. A CT scan will generally show the presence (or absence) of an abscess, which is always accompanied by ethmoid sinusitis. If an abscess is present, it will require surgical drainage as soon as possible, so the patient should be referred to an otolaryngologist.

However, if the condition is severe ethmoid sinusitis with-out abscess, it may be treated with intravenous antibiotics and nasal flushes with decon-gestant nose drops. Severe eth-moid sinusitis will often resolve with nonoperative therapy, but if the patient's condition wors-ens, then surgery is indicated.

Sphenoid Sinusitis

Sphenoid sinusitis can cause **ophthalmoplegia**, meningitis, and even **cavernous sinus**

thrombosis. Cavernous sinus thrombosis is a complication with even more grave implications than meningitis or brain abscess, and it carries a mortality of approximately 50 percent. The veins of the face that drain the sinuses do not have valves, and they may drain posteriorly into the cavernous sinus. **Infectious venous thrombophlebitis** can spread into the cavernous sinus from a source on the face or in the sinus. The most common cause of this serious infection is rhinosinusitis. The nerves that run through the cavernous sinus are the oculomotor (III), trochlear (IV), and first and second divi-sions of the trigeminal (V) and the abducens (VI). A patient who has dou-ble vision and rhinosinusitis should be assumed to have cavernous sinus thrombosis until it is ruled out by a CT and/or MRI scan. The preferred treatment is high-dose intravenous antibiotics and surgical drainage of the **paranasal sinuses**. Anticoagulation is also a consideration in the treat-ment regimen.

Fungal Sinusitis

Although fungal elements are commonly found in the nasal cavity of nor-mal patients, some patients develop a sensitivity or immunoreactivity to fungi, resulting in **allergic fungal sinusitis**. This allergic disorder to fungi can result in severe symptoms of chronic sinusitis and significant inflam-mation in the sinonasal mucosa due to a preponderance of eosinophils. Effective treatment requires surgery to remove the offending fungal mucin. Fungal spores can also get trapped in a sinus, where they germi-nate and fill the sinus with debris, forming a “fungal ball” or **mycetoma**. Typically, mycetomas do not cause a significant inflammatory response, and they are easily cured by surgical removal. If a patient is immuno-

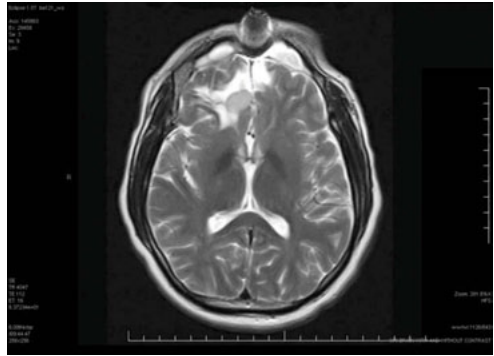


Figure 9.2.

This axial MRI depicts a patient with fluid in his right frontal sinus. The infection has spread retrograde and he has developed a frontal abscess.

compromised or has diabetes, certain fungal infections (e.g., **mucormycosis**) can become “invasive,” resulting in destruction of the sinus with erosion into the orbit or brain. These invasive fungal infections constitute an ENT emergency, since they are life threatening and can advance quite rapidly (see Chapter 4, ENT Emergencies, for more details).

Nasal Obstruction

Nasal obstruction is another complaint seen regularly in the ENT office setting. A frequent cause of nasal obstruction is **septal deviation**. These patients often present with histories of nasal obstruction, possibly complicated by sinusitis and headaches.

They may also snore and have obstructive sleep apnea syndrome. Although surgery readily corrects the nasal obstruction and may reduce chronic sinusitis and headaches, studies have shown that correction of the nasal obstruction rarely cures sleep apnea, but it may improve continuous positive airway pressure machine tolerance. When the obstruction involves the nasal pyramid, it, too, must be corrected by **rhinoplasty**. Rhinoplasty involves controlled chisel cuts of the bones (**osteotomies**) on either side of the nose and placement of the bones into the correct position.

A splint is used to hold this position for a week after surgery. Rhinoplasty can be combined with trimming of the nasal cartilage to subtly change the contour of the tip of the nose. When the obstruction involves the softer, cartilaginous middle third of the nose and/or the nostril openings, then nasal valve repair may be indicated. This surgery may entail placing cartilage grafts to widen or strengthen the lateral wall of the nasal cavity to relieve the nasal obstruction. This surgery can be performed concomitantly with a septoplasty or rhinoplasty.

Nasal Polyps

Nasal polyps are localized, extremely edematous nasal or sinus mucosa. They are a frequent cause of nasal blockage. Microscopically, they are essentially full of water. They can enlarge while in the nose, and obstruct either the nose or the ostia through which the sinuses drain. The exact

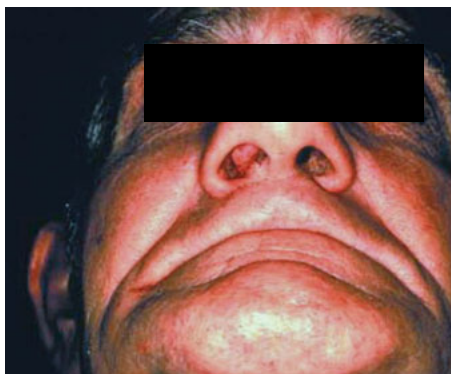


Figure 9.3.

View of the nose of a patient with a deviated nasal septum. Note that the cartilaginous septum extends into the right nostril, resulting in impaired airflow. Most septal deviations are not as dramatic as this, and can be visualized only with rhinoscopy.

RHINOLOGY, NASAL OBSTRUCTION, AND SINUSITIS

cause of polyps is not known, but 50 percent of patients who have polyps also have allergies, so patients with polyps should be evaluated for allergies. Polyps usually respond very well to a course of systemic steroids followed by continuous intranasal steroid sprays. Surgery may be indicated if the polyps reoccur frequently or do not respond to treatment.

Patients with allergic rhinitis and chronic sinusitis develop these grapelike swellings that protrude into the lumen, causing obstruction and **anosmia**. These polyps are often associated with **asthma**. Medical therapy with inhaled nasal steroids as well as short bursts of systemic steroids often produces good long-term control of the disease. Surgical removal provides relief, but unfortunately, recurrence is common. Samter's triad, consisting of asthma, an allergy to aspirin, and nasal polyposis, is a particularly difficult-to-treat form of this disease. **Unilateral nasal polyps** may be a manifestation of a **neoplasm**, and must be referred to an otolaryngologist for evaluation. Polyps in children are uncommon and should prompt a workup for cystic fibrosis.

Another relatively frequent cause of nasal blockage is **rhinitis medicamentosa**. This syndrome develops when people repeatedly use decongestant nasal sprays over a long period. The rebound effect causes them to need the spray just to breathe. After prolonged use, the mucosa becomes quite inflamed. The treatment is discontinuation of the decongestant sprays. Symptoms can be reduced by intranasal steroid spray, occasionally accompanied by short bursts of systemic steroids. Cocaine abuse can also cause this problem. Cocaine may also induce **ischemic necrosis in the nasal septum** because of the amount of vasoconstriction. The ischemia then may result in a **nasal septal perforation**, which interferes with nasal airflow and is very difficult to repair surgically.

Some patients have a very straight septum with no nasal polyposis or inflammation, but they suffer from chronic rhinosinusitis due to blockage of sinus drainage. The **uncinate process** comes very close to the **ethmoid bulla**, forming the **infundibulum** through which the **maxillary sinus**

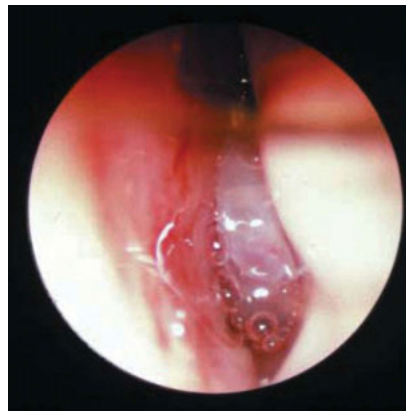

Figure 9.4.

Photograph of a nasal polyp. Nasal polyposis is a common ailment that results in nasal obstruction and drainage. Most patients require medical treatment with topical steroids and antibiotics, as well as surgical removal of polyps and diseased tissue.

drains. Only one mm of swelling in the mucosa in this area will obstruct the sinus **ostium**. Patients with chronic obstruction in this area and recurrent sinusitis often undergo surgery to either dilate the osteomeatal complex with a balloon, or remove the uncinate process and open the bulla to let the ethmoid and maxillary sinuses drain more freely. After the surgery, a small amount of swelling will not obstruct the drainage flow from these sinuses. This procedure is done completely through the nose endoscopically, and patients tolerate it very well.

Nasal Masses

By far the most common nasal masses encountered by physicians are nasal polyps. As you might expect, they present with symptoms caused by the mass obstructing the nose or sinuses. Obstruction of the natural ostium of the sinus will cause a backup and may lead to sinusitis. Other types of intranasal masses include inflammatory etiologies, such as pyogenic granuloma, Wegner's granulomatosis, and sarcoidosis. Neoplasms, including inverting papilloma, juvenile nasopharyngeal angiofibroma, esthesioneuroblastoma, sinonasal undifferentiated carcinoma, adenocarcinoma, and other malignancies, are fortunately not as common.

RHINOLOGY, NASAL OBSTRUCTION, AND SINUSITIS

QUESTIONS

1. A patient complains of fatigue, low-grade fever, purulent rhinorrhea, and headache that resolves within seven days. The most likely diagnosis is a _____.
2. A patient had a typical cold that did not resolve in 10 days and has now had fatigue, purulent rhinorrhea, low-grade fever, and headache for three weeks. The most likely diagnosis is _____.
3. Another patient has similar symptoms for more than three months. This patient has _____.
4. A common cause of nasal obstruction that is easily corrected by surgery is a _____.
5. Triad asthma (Samter's triad) consists of asthma, nasal polyposis, and _____.
6. Unilateral nasal polyps can either be caused by or be a manifestation of a _____, and therefore warrant referral to an otolaryngologist.
7. Any patient with symptoms of sinusitis and _____ should be referred to an otolaryngologist immediately.
8. Patients should see an otolaryngologist if they have ____ episodes of sinusitis per year or if they have any _____ of sinusitis.

ANSWERS

1. Common cold
2. Acute rhinosinusitis
3. Chronic rhinosinusitis
4. Deviated septum
5. Aspirin allergy
6. Neoplasm
7. Double vision
8. 3–4, complication

Allergy

Over 20 million Americans suffer from **inhalant allergies**. Symptoms are **nasal congestion, clear rhinorrhea, itchy watery eyes**, and sometimes ear or palatal itching, post-nasal drip, and throat irritation. **Fatigue** is common, caused by sleep disturbance from nasal obstruction, perhaps with other immune contributors. Symptoms may occur only in certain seasons or locations. If one parent has inhalant allergies, **a child has about a 30 percent chance of developing allergies**. If both parents have allergies, this increases to about 60 percent. The percentage of the population with allergy problems has been increasing in developed countries. One possible explanation for this is that the infectious diseases more common in less developed countries help tilt an individual's immune system more toward the T-helper 1 (Th1) system, minimizing the chance of developing the Th2-mediated atopic reaction, and the resulting allergic symptoms.

Allergic symptoms are initiated by inhalation of **dander, pollen, mold spores**, or other antigens. Typically, **trees** pollinate and cause symptoms in the spring, **grasses** pollinate in the summer, and **weeds**, such as ragweed, pollinate in the fall. Allergens, such as **house dust mites, cockroaches**, animal dander, and molds, can cause symptoms year-round. Allergies represent an **abnormal immune response to an environmental protein** tolerated by the majority of people.

At least 20 percent of the U.S. population has the genetic capacity to produce **excess immunoglobulin E (IgE)**, the immunoglobulin that mediates allergic symptoms. Having inhalant allergy symptoms requires an initial contact with that specific allergen, which results in development of the allergen-specific IgE. In this **Gell & Coombs Type I** hypersensitivity, the allergen-IgE populates the outside of **mast cells** in tissues. On recontact, the allergen binds to this allergen-specific IgE on the mast cell, triggering release from the mast cell of preformed allergic mediators (**histamine, proteoglycans, proteases**), causing immediate symptoms, and initiating the production of further allergic mediators (**leukotrienes** and prostaglandins) responsible for the late-phase allergic response (3–12 hours later).

There are three mainstays of treating inhalant allergies:

- Pharmacotherapy
- Avoidance of the provoking allergen
- Immunotherapy

Pharmacotherapy

Pharmacotherapy helpful for allergic symptoms includes antihistamines (oral or nasal topical), nasal steroid sprays, decongestants, topical nasal cromolyn, or oral antileukotrienes. Allergy pharmacotherapy is often started empirically, before allergy testing. If symptoms respond well, the medication can be continued as needed, and allergy testing may not be necessary. Allergen avoidance requires determining what allergens are specific triggers for an individual, either by skin testing or **in-vitro testing** for elevated levels of IgE. In-vitro testing is preferred for patients who:

- Are pregnant
- Have poorly controlled asthma
- Have dermatographism
- Take a beta blocker medication
- Take a tricyclic antidepressant
- Take a monoamine oxidase inhibitor
- Have a history of severe anaphylaxis

Antihistamine medications (oral or nasal) must be discontinued three to five days before testing to avoid false negative results. Antileukotrienes, nasal steroid sprays and oral and topical decongestants may be continued without interfering with allergy skin testing.

Allergen Avoidance

Specifics of **allergen avoidance** depend on the allergen. House dust mite sensitivity requires bedroom dust minimization, including mattress and pillow covers, special carpet cleansers, HEPA filters, etc. Cat sensitivity responds to avoiding cats, and mold sensitivity requires avoiding damp and musty areas.

Immunotherapy

If pharmacotherapy is unsuccessful in controlling the allergic symptoms, allergy testing and consideration of **immunotherapy** is indicated. Immunotherapy is the only treatment option capable of altering the immune system's response to allergens. Begun with a very tiny dose that is gradually increased to a known-to-be-effective target dose, immunotherapy decreases antigen-specific IgE, increases antigen-specific immunoglobulin G (IgG), induces antigen-specific T-cell "tolerance" to the antigen, and tilts the immune system further toward the Th1 response. Immunotherapy has traditionally been administered via subcutaneous injection. In the pediatric population, sublingual immunotherapy is gaining favor.

Both allergy skin testing and immunotherapy have the potential to cause severe or fatal **anaphylaxis**. Both should be undertaken with caution in a setting where emergency supplies, equipment, and trained personnel are immediately available. Since poorly controlled or worsening asthma is the main risk factor for developing such anaphylaxis, questions about current asthma status (or actual peak flow measurement) are appropriate on each test or treatment day. Inhalant allergies, although in themselves rarely life-threatening, have a major negative impact on quality of life. Symptom improvement or resolution with the above approach is usually possible.

CHAPTER 10

QUESTIONS

1. In inhalant allergies, the T-helper cell system is abnormally weighted toward the _____.
2. If both parents have inhalant allergies, a child has a _____ percent chance of developing allergies.
3. People with allergies produce excess Ig_____.
4. Trees typically pollinate and cause allergy symptoms in the season of _____.
5. Most inhalant allergies are a Gell & Coombes Type _____ hypersensitivity reaction.
6. IgE populates the outer surface of _____ cells.
7. Mast cells contain preformed allergic mediators, including _____, or _____, or _____.
8. Medications that are a contraindication to allergy skin testing include _____, or _____, or _____.
9. The main medication that must be discontinued three to five days before skin testing is _____.
10. The most serious adverse reaction to allergy skin testing or immunotherapy is _____.

72

ANSWERS

1. Th2 side
2. 60 percent
3. E
4. Spring
5. I
6. Mast
7. Histamine, proteoglycans, proteases
8. Beta blockers, tricyclic antidepressants, monoamine oxidase inhibitors
9. Antihistamines
10. Anaphalaxis

How to Read a Sinus CT Scan

The standard radiographic study for evaluation of sinus disease is the sinus CT scan performed in the **coronal plane** without intravenous contrast. As with other radiographic studies, a few principles go a long way:

1. Look at the name
2. Look at the date
3. Look at the orientation—right versus left

The convention of designating sides for head and neck CT scans varies from institution to institution. You **cannot assume** that right is right and left is left when the film is positioned so you can read the name. You must see an *R* or an *L*.

There are **four radiographic densities: air, fat, water, and bone**. Remember this very basic principle: When two structures of the same radiographic density are adjacent, the border between them is obscured. For example, if you cannot see the right heart border on a **posterior-anterior** chest x-ray, the lung next to the heart (right middle lobe) has the same density (water density) as the heart. Likewise, **pus or fluid in the sinus has the same density as thickening of the sinus mucosa**. The relative density of bone and other structures can be manipulated by the scan reader as either bone window (demonstrates clear bone detail) or soft tissue window (bones too bright, soft tissue easily visualized).

When you view CT scans, you must look at more than one image. If you do not know what a structure is, follow it through adjacent slices, and you'll usually be able to easily identify it. Systematically reviewing any imaging study in sequence is critical to recognizing subtle abnormalities. Although the novice viewer routinely examines the maxillary sinuses first, you should carefully evaluate the orbits, orbital walls, skull base, maxillary alveolus, nasal septum, and sinuses in order. Remember that the ethmoid sinuses lie between the orbits, the maxillary sinus below the orbits, frontal

HOW TO READ A SINUS CT SCAN

sinuses above, and sphenoid sinuses behind. You should carefully study every x-ray, MRI, or CT scan that you encounter, so you can learn to recognize common anatomic variants and distinguish them from true pathology. Here are three common anatomic variants encountered on coronal CT scans of the sinuses.

- Deviated nasal septum
- Asymmetry of sinuses, including size, shape, presence of septas, etc.
- An air cell within the middle turbinate (concha bullosa)

Abnormalities include fluid, mucosal thickening, bony fractures, cysts, and tumors, as shown in Figures 11.1 and 11.2.

The Osteomeatal Complex

The most significant area to examine in a patient with sinus complaints is the **osteomeatal complex (OMC)**. Coronal CT scans are used in the evaluation of sinus disease because they are best for visualizing the OMC. The OMC is the region through which the maxillary, ethmoid, and frontal sinuses drain in the nose. An obstruction of the OMC will frequently lead to sinusitis, and is often due to mucosal edema or anatomic abnormalities. Neoplasm should always be on the differential diagnosis.

The anterior-most ethmoid sinus—the **agger nasi cell**—is frequently clouded. Edema in this sinus may be associated with obstruction of the nasal frontal duct and results in frontal sinusitis. This

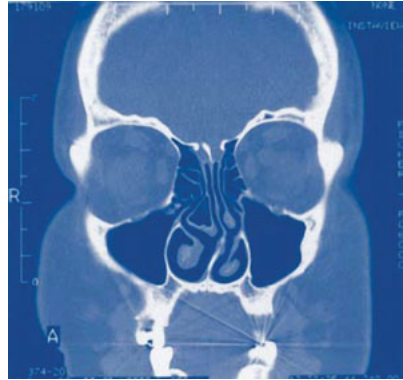


Figure 11.1.

A coronal CT scan of the sinuses in a patient with deviated nasal septum and an air cell (concha bullosa) within the right middle turbinate. The surgical correction of nasal obstruction in this patient would require partial middle turbinectomy, as well as correction of the deviated nasal septum.

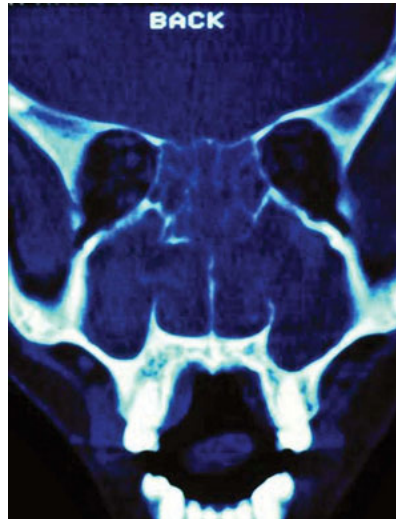


Figure 11.2.

A coronal CT scan of the sinuses demonstrating complete opacification of the nasal cavity and ethmoid and maxillary sinuses. This image represents pansinusitis with polyps; however, neoplasms may present in a similar fashion.

area is best visualized on a sagittal CT scan. In most instances, sinusitis is manifested by loss of aeration of multiple sinuses, usually involving both sides. This is visible as water density, which may be swelling of the mucosa, polyps, fluid, or pus. Clouding of a single sinus (unilateral disease) suggests an unusual cause, such as a tumor.

A sinus CT scan is not the first step in the evaluation of a patient with chronic sinusitis. Moreover, it is not necessary in the evaluation of all patients, since the history and physical, particularly nasal endoscopy, will often identify the source of the pathology. Medical therapy, consisting of antibiotics, decongestants, and topical steroids can be initiated based on clinical criteria. Should the patient fail this treatment or experience multiple episodes of sinusitis, a sinus CT is essential to determine if there is an anatomic cause for the problem. If surgical intervention is being considered, the CT scan provides information vital to the pre-operative plan. It should be noted that all patients with nasal polyposis have chronic sinusitis, typically involving all sinuses. Unilateral nasal polyposis associated with unilateral sinusitis suggests tumor (most commonly **inverted papilloma**, a benign growth caused by human papilloma virus).

Mucosal thickening of the sinuses, particularly the ethmoid sinuses, persists six to eight weeks following a URI. Each of us can expect to suffer three or four URIs per year, so random sinus CT scans performed on a population will demonstrate a high incidence of mucosal thickening. As a result, it is important that the CT scan be obtained after a patient has been maximally treated, and the disease is at its nadir or most improved state. On a CT scan, it is impossible to differentiate between sinus clouding due to a common cold and that due to bacterial sinusitis.

Remember: The best way to learn to look at any x-ray or imaging study is to carefully and systematically examine as many as possible.

HOW TO READ A SINUS CT SCAN

QUESTIONS

1. The first thing you should look at on any x-ray or CT scan is _____.
2. The second thing you should look at on any x-ray or CT scan is _____.
3. The third thing you should look at on any x-ray and especially on a CT scan is _____.
4. The four radiographic densities are _____, _____, _____, and _____.
5. When two structures of the same radiographic density are adjacent to each other, the border between them becomes _____.
6. CT scans are typically printed in one of two densities, _____ density and _____ density.
7. CT scans are typically obtained in the coronal plane, because this view best demonstrates the _____.
8. Common anatomic variants encountered on coronal CT scans include _____, _____, and _____.
9. The key area that must be visualized on a sinus CT scan is the _____.

ANSWERS

1. The name
2. The date
3. Identification of right and left side
4. Air, fat, water, bone
5. Obscured
6. Bone, soft tissue
7. Osteomeatal complex (OMC)
8. Asymmetries of sinuses, deviated septum, and concha bullosa
9. Osteomeatal complex (OMC)

Maxillofacial Trauma

When you are treating maxillofacial trauma, the basic (ABC) tenets of trauma management hold:

- You must secure an **Airway**
- You must make sure the patient is **Breathing** and ventilating adequately
- You must ensure adequate **Circulation** by stopping bleeding and providing fluid replacement
- You must ensure that no **C-spine** fracture is present

Always consider the airway first. Healthcare professionals always wonder whether a patient should have a cricothyrotomy or intubation. This is sometimes a judgment call. One way to think about this decision is to review a checklist of ways to secure the airway. Do not forget that the most common cause of airway obstruction in a patient with an altered level of consciousness is the tongue falling back into the throat. This can be treated by a **jaw lift maneuver**, an **oral airway**, or a **long nasal airway**. Also consider the possibility of a foreign body (dentures in adults; balloons, small toys, food, etc., in children) obstructing the airway. If the cause of airway obstruction is not so simple, however, the quickest and easiest method of securing the airway is **endotracheal intubation** through the mouth. This requires placing a laryngoscope down through the mouth to the larynx (**direct laryngoscopy**) and lifting up. The **vocal cords** are seen, and then the tube is placed between the vocal cords and into the trachea.

But this technique may not work for two reasons. The first reason is a cervical spine injury. Direct laryngoscopy requires movement of the neck, and if the neck is already broken, it can possibly move during the procedure and compress the spinal cord, causing paraplegia, quadriplegia, or death. Therefore, oral endotracheal intubation is not to be performed if a patient has either a known C-spine fracture or a likelihood of having a C-spine fracture that has not been ruled out by a lateral neck film. Intubation in a trauma situation requires that **in-line cervical traction** be

applied to the head by someone other than the intubating physician at the time of intubation. The second reason you might not be able to perform oral intubation is massive facial and neck trauma with distortion of landmarks and bleeding.

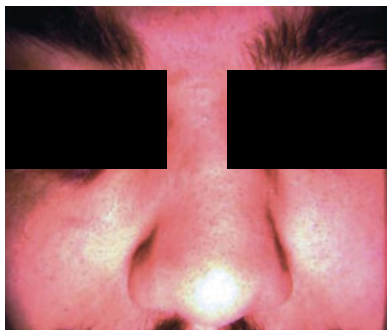

Figure 12.1.

Nasal fracture. Note that the bony nasal pyramid has been shifted toward the patient's left. Most commonly a right-handed individual will strike a patient's nose and shift the bony pyramid toward the patient's right. Repair is straightforward, but should be completed within 5–7 days to ensure optimal outcome.

This patient might have had a lateral C-spine film that showed no C-spine fracture, but at direct laryngoscopy, all you can see is blood and disrupted tissue. This patient would obviously need a surgical airway. You would perform a cricothyrotomy, unless there is concern over a **fractured larynx (widened thyroid cartilage, subcutaneous air [crepitus], neck bruising, hoarseness, coughing up blood)**, in which case, a tracheotomy is the procedure of choice. Remember, normal lateral C-spine film does not completely rule out a C-spine fracture.

Next, consider breathing and ventilation. If you cannot perform an oral intubation, you can sometimes perform a **fiberoptic nasotracheal intubation**. In this case, an endotracheal tube is passed through the

nose down into the **hypopharynx**, guided by a fiberoptic endoscope placed through the endotracheal tube. With the endoscope, you can see when the tube approaches and is advanced into the larynx. You must wait until just after an expiration, because the ideal time to push the endoscope through is when the patient breathes in, opening the vocal cords. Once the endoscope is in the trachea, the tube is passed over the scope, and the endoscope is then removed. The advantage of the fiberoptic nasotracheal intubation technique is that the neck is not manipulated at all, so it is still a viable option, even if a C-spine fracture has not been ruled out. Fiberoptic nasotracheal intubation is best performed on an awake patient who is able to sit upright. Tissue collapse makes this procedure more challenging when patients are supine. This technique is not feasible if visualization is obscured by secretions, blood, or swelling. Also, if there is a **severe midface injury** with possible **cribriform plate fracture**, passage of a nasogastric or blind nasotracheal tube is contraindicated because the tube may pass into the brain.

You've gone through your checklist as above and have determined that the patient's tongue is not the problem. You cannot perform an oral intubation (perhaps because the lateral C-spine film shows a broken neck), and you cannot perform a nasotracheal intubation (perhaps because the patient has profuse oral bleeding). You now know that the only option is a surgical airway. The indication for an emergent ("bedside") surgical airway, either cricothyroidotomy or tracheotomy, is in a patient who is unable to be intubated and unable to be successfully ventilated with a mask. The exception to this is a patient with severe laryngeal trauma, where mask ventilation or intubation could worsen the situation.

The methods of choice are a tracheotomy and a cricothyrotomy. Which procedure is performed depends on the level of expertise available. In an emergency, cricothyrotomy may be chosen over tracheotomy, because it is quicker and is accomplished through the relatively thin and more superficial cricothyroid membrane. You should learn to palpate and recognize the cricoid cartilage. Try it on yourself; the membrane is just above the cricoid cartilage and below the thyroid cartilage (the Adam's apple).

Other Aspects of Maxillofacial Trauma Management

Anyone who has sustained enough trauma to break a facial bone should be assumed to have a C-spine fracture until this is ruled out. Rule #1 in maxillofacial trauma management is secure the **A**irway, **B**reathing, and **C**irculation. Rule #2 is rule out a C-spine fracture, if it has not already been done. Rule #3 is evaluate the patient completely. Look in the ears for hemotympanum, which can signify a temporal bone fracture. Check that the facial nerve works on both sides, since a complication of temporal bone fracture may be facial nerve paralysis (an otolaryngologist should be consulted for any temporal bone fracture). Next, palpate the orbital rims to ascertain whether or not a **malar (tripod) fracture**

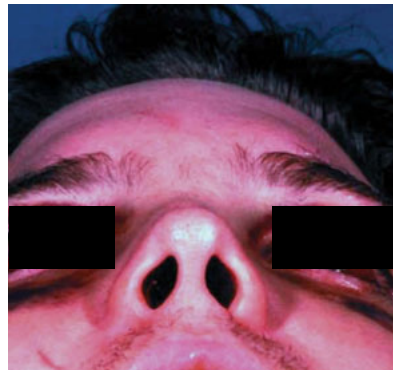


Figure 12.2. Bilateral periorbital ecchymoses and subconjunctival hemorrhages. This may be due to soft tissue trauma only, or it may be a manifestation of an underlying fracture.

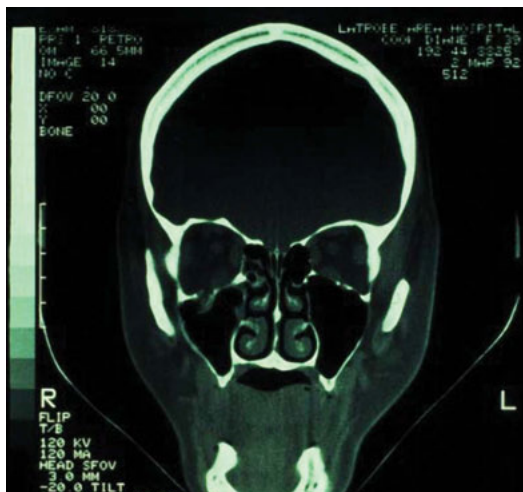

Figure 12.3.

Coronal CT scan demonstrating a blowout fracture of the right orbital floor. This fracture often results in entrapment of the inferior rectus muscle and limitation of upward gaze.

has occurred. Check the patient for trismus. Make sure the patient is not experiencing double vision, which may occur when an **orbital blowout fracture** happens and the **inferior rectus** or **medial rectus** becomes entrapped. Make sure that there is no **infraorbital nerve hypesthesia**, which can also occur with a blowout fracture or a tripod fracture.

Next, evaluate the nose. In general, isolated nasal fractures can be reduced up to 14 days after the fracture, if they cause a cosmetic deformity or airway obstruction.

It is easier to do when there

is less swelling, and usually the swelling goes down by five to seven days. If the septum has been broken, you must rule out a **septal hematoma**—the formation of a blood clot between the **perichondrium** and cartilage that disrupts the nourishment of the cartilage. This can result in **septal necrosis**, with subsequent perforation due to either a loss of nutrition from the perichondrium or a secondary infection of the hematoma, generally with *Staphylococcus aureus*. These conditions are treated by incision, drainage, and packing to ensure that the blood and bacteria do not reaccumulate.

Radiographs are not particularly helpful in cases of a broken nose, because old fractures cannot be distinguished from acute ones. Generally, inspection and palpation are the best ways to diagnose a broken nose. Uncomplicated nasal fractures are treated with antibiotics, pain medicine, a decongestant nasal spray, and a referral for reduction within three to five days.

Continuing with the exam, evaluate the stability of the maxilla by grasping the maxilla area just above the front teeth and applying a gentle rocking motion. If the maxilla is unstable, you will feel it move separately from the face. This is a **LeFort fracture** and will require **surgical plating**. A complete bilateral LeFort III fracture is rare, and involves massive trauma that disarticulates the face from the skull. It is usually accompanied by spinal

fluid leakage. The remaining soft tissue attachments consist largely of the optic nerves, thus the *gentle* rocking. A CT scan will elucidate the situation if you are unsure.

Check the patient for **cerebrospinal fluid (CSF)** rhinorrhea, since a basal skull fracture or temporal bone fracture can leak into the middle ear, which drains down into the eustachian tube and out the nose. Alternatively, the site of the leak may be just above the cribriform plate. Remember that CSF mixed with blood produces a ring sign on the sheets or on filter paper, and also that CSF has a measurable glucose concentration, while mere nasal secretions do not. β 2-transferrin is a protein found only in CSF, so a positive test is diagnostic of a CSF leak.

Next, evaluate the mandible. Examine the patient's occlusion and ask if his or her teeth fit together like they always have. Mandibular fractures are generally treated with a combination of intermaxillary fixation and the surgical application of plates.

Trauma to the neck may injure the larynx or trachea. For example, blunt trauma from a steering wheel can cause fracture of the thyroid cartilage, cricoid, or both. A complete crush is nearly always fatal, unless someone handy with a knife is waiting to do an immediate cricothyrotomy. Lesser injury generally results in progressive hoarseness and **stridor**. The only initial physical finding may be **cervical ecchymosis**. Check for loss of cartilaginous landmarks, and feel for subcutaneous air (**subcutaneous emphysema**). Any positive finding is an indication for further evaluation with laryngoscopy, possible CT, and observation. Penetrating wounds to the neck may also indicate injury to the vascular structures, esophagus, or airway. Immediate expert evaluation will determine if surgery is required.

CHAPTER 12

QUESTIONS

1. The first priority in management of maxillofacial trauma is securing the _____.
2. In an unconscious patient, the most common cause of airway obstruction is _____.
3. Two reasons that oral endotracheal intubation may be contraindicated are _____ and _____.
4. A contraindication to blind nasotracheal or nasogastric intubation is _____.
5. The nerve that is commonly not evaluated upon initial presentation, but whose management depends greatly on the examination at the initial time of presentation is the _____ nerve.
6. A fractured nose can be reduced in up to 14 days without complications; however, a _____ must be ruled out at the time of the initial fracture.

ANSWERS

1. Airway
2. Prolapse of the tongue posteriorly
3. A broken neck, massive trauma with distortion of landmarks and bleeding
4. Cribriform plate fracture
5. Facial
6. Septal hematoma

Facial Plastic Surgery

Facial plastic surgery constitutes a significant part of the practice of otolaryngology. Otolaryngologists in both Great Britain and the United States were founding fathers of plastic surgery as a medical specialty. While extra training through a fellowship in facial plastic surgery is available for otolaryngologists who wish to specialize in this area, all otolaryngologists are trained in these techniques as a part of their residency. Common procedures vary from the functional—the **repair of traumatic facial lacerations and fractures** or **reconstruction** after skin cancer and head and neck cancer—to purely **cosmetic** procedures, such as a facelift (**rhytidectomy**) and injection of soft-tissue fillers or neurotoxins in the office. Some procedures, such as **rhinoplasty** (corrective nasal surgery), may be both cosmetic and functional (to improve breathing). Here are some of the

basic principles involved in taking care of patients with injuries or deformities of the face.

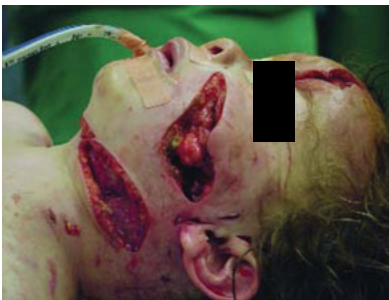

Figure 13.1.

This patient was an unrestrained passenger in a motor vehicle accident. He has multiple facial lacerations, contusions, and fractures. Remember the ABCs in his management.

Facial Trauma

It is often very striking when patients present after suffering massive facial trauma. Soft-tissue defects may be present, exposing the underlying anatomy. They may also have some areas of tissue that are missing. Facial disfigurement from fractured and displaced facial bones may be present. Often, there is blood, mud, or other foreign matter in the wound.

The workup should begin with the basics of trauma management: **stabilization of the ABCs**, **evaluation of all other associated injuries**, and administration of **antibiotics** and a **tetanus shot** (as indicated). Do not forget to check to be sure that the **cervical spine** has been cleared.

Smaller lacerations can often be repaired satisfactorily in the emergency room. Larger, more complex lacerations may be better repaired in the operating room, where the patient can be made more comfortable and the wound thoroughly cleaned. Pay particular attention to deep wounds that traverse the course of the **facial nerve** or **parotid duct**, as these structures may be injured as well. Lacerations that involve the eyelid may have injured the globe, and ophthalmic consultation should be considered.

Once these other considerations have been satisfied and the wounds are ready to be repaired, several principles may be helpful. First is careful reapproximation of all remaining tissue. After the wound has been anesthetized and cleansed, it becomes more obvious where the tissue needs to go. It is important to be meticulous when you are repairing these wounds, somewhat like putting together a jigsaw puzzle. Line up known lines first: the vermilion border of the lips, **free margins of the nose and eyelids**, edges of eyebrows, and parts of the pinna must be perfectly aligned. Second, careful handling of soft tissue is important to avoid crushing the delicate tissue edges further. It may take more than one effort to repair some of these wounds properly, and removing any misplaced sutures and starting over is not uncommon. Buried resorbable sutures of material, such as polyglactan or monocaproic acid, help to reduce the tension placed on the wound (which is an important determinant of reducing scar formation). Last, when closing the final layer, it is important to be sure that the skin edges are everted and not inverted, as this will lead to a depressed scar that is more visible.

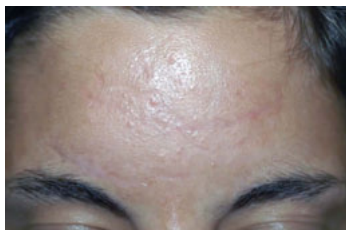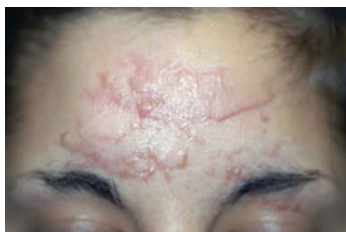On the face, 5-0 or 6-0 suture is usually adequate, and resorbable mild suture, such as fast-absorbing gut, or a permanent suture, such as nylon or polypropylene, is best. Immediately after a wound is closed, it fills with serum, which clots. This serum prevents water from entering the wound. Wounds may be allowed to get wet within a few minutes of closure as long as the microscopic clot is not disrupted. Thus, you may tell patients they can get their wound wet, as long as they do not scrub it and the water is reasonably clean. Showering is fine; swimming in a lake probably is not. Instruct them to keep antibiotic ointment or petrolatum jelly on the wound. This will help it retain moisture and reduce crusting until the skin has healed (usually about a week on the face).

Sutures on the face should be removed at three to five days, while those on the ear and scalp should be allowed to remain somewhat longer, usually around seven days. It is important for patients to realize that scars take a minimum of one year to cosmetically mature. The time course usually involves the scar turning red, with the maximum redness occurring at

approximately six weeks. The scar then tends to fade to purple and brown before eventually turning white. In general, scar revisions are not performed until a scar has fully matured. Sunscreen should be used for at least the first year after the injury, because scars can become **hyperpigmented** with exposure to the sun. If **hypertrophic** scars tend to form, steroid injections directly into them can help. Recently, early **dermabrasion** (like sanding a piece of wood), at six to eight weeks, has been used with success in reducing scarring. Timing of this procedure is critical. Covering the wound with silastic sheeting may also decrease scars.

In addition to soft-tissue injuries, repair of facial skeletal fractures is often necessary. The most common facial fracture is a broken nose. Depending

88



Figures 13.2 a, b.

Pre- and post-op dermabrasion of traumatic forehead scars from a car accident.

on the degree of this injury, management may be as simple as control of bleeding with ice and nasal spray, or may require surgery. Most significant nasal fractures are obvious on physical exam. Radiographs are not particularly helpful for diagnosis, but are commonly taken for documentation purposes. Reduction of displaced fractures can be done in the emergency room if sedation is available, but may require a trip to the operating room. Once the bones are manually moved to their original position, a “splint” or cast is commonly placed both internally and externally to hold the bones in position while they heal. More significant fractures, such as those of the mandible or midfacial skeleton, are typically evaluated by CT scanning. If the bones are displaced, surgery (open reduction and internal fixation) may be needed. Titanium microplates are commonly used to repair

facial fractures now. Some maxillomandibular fractures can be managed without surgery (closed), using temporary “braces” (arch bars) or a soft diet.

Septorhinoplasty

Perhaps the most common form of facial plastic surgery that an otolaryngologist performs is **septorhinoplasty**. In this operation, the deviated septum is straightened, and the outside of the nose may also be changed in form through various surgical maneuvers. The most common procedure is straightening the septum (**septoplasty**), which is performed through the

nostrils and entails realignment of the septum into the midline. Changing the external contour of the nose is called **rhinoplasty**. The most important part of rhinoplasty is maintaining or improving the airway, so a septoplasty is often performed as part of this procedure. Common indications for rhinoplasty include previous trauma, with resulting crooked nose as well as a dorsal hump. Many patients undergo rhinoplasty to achieve better proportion between the size of their nose and their face, or to improve the shape of the tip alone in an otherwise attractive feature. Rhinoplasty can be accomplished using incisions that are entirely inside the nose (closed) or combined with a small incision across the columella (open) for improved access for placing grafts and sutures.

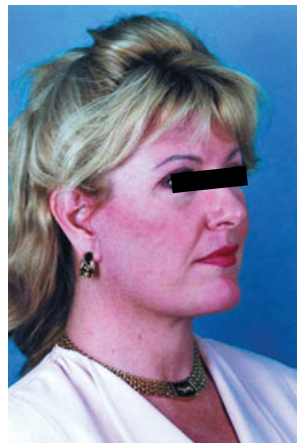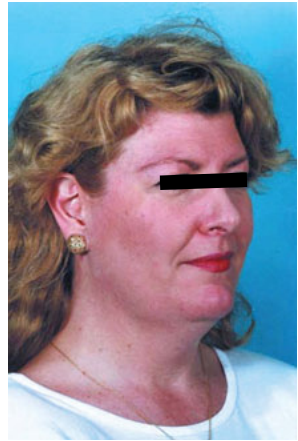Facial Rejuvenation

Rhytidectomy

Rhytidectomy or “facelifting” is a much more common procedure than in the past. There are many variations in technique, but most involve an incision hidden around the ear, with undermining of the skin and tightening of the muscle and tissue layers underneath. This is commonly combined with other procedures for more thorough facial rejuvenation.

Blepharoplasty

Blepharoplasty is often performed by otolaryngologists who perform facial plastic surgery. When the upper eyelid skin becomes redundant, it can actually obstruct the upper field of vision. When this is the case, the skin can be removed to allow better vision. While this is the main functional benefit of a blepharoplasty, patients often also desire some cosmetic changes around their eyes. Bulges that occur below the eyes consist of orbital fat pressing against a weakened orbital septum. This fat can be resected, along with extra



Figures 13.3 a, b

Pre- and post-op photographs of a woman who has undergone facial rejuvenation. She has had surgery to her eyelids (blepharoplasties), removal of fat from her neck (liposuction), and resection of excessive facial skin (facelift). Improvement in facial appearance is often dramatic (as in this case), and secondary benefits through enhancement of self-esteem may be even more dramatic.

skin and muscle. However, this must be done with great care, as there is little margin for error, especially around the lower lid.

Occasionally, the eyebrows lie below the level of the superior orbital rim and may be a part of the problem as well. This is called brow **ptosis** and can cause an apparent excess of skin in the upper lid. Elevation of the brow with a **brow lift** can reduce redundant skin of the eyelids and is an important part of facial rejuvenation in some patients.

Nonsurgical Facial Rejuvenation

Improvement of facial wrinkles (rhytids) can be achieved through several methods. One of the most popular treatments is the injection of medicines known as **neurotoxins** to weaken facial muscle contractions and improve the wrinkles caused by them. Deeper rhytids or folds may be helped with the injection of fillers. Fillers can also be used to restore volume to the lips and other areas that have lost volume as part of the aging process. Chemical peels and laser resurfacing remove the outer layers of the skin, and the new skin formed with healing has less sun damage and wrinkles. Many types of lasers are now available to treat a variety of cosmetic concerns in the office setting with little down time for the patient. Improvement in sun spots, birthmarks, and unwanted hair are just a few of the problems commonly treated. All of these procedures are part of the office-based practice of many otolaryngologists or facial plastic surgeons.

Otoplasty

Some people have ears that stand out further than normal from their head. This is usually congenital, and anatomically is due to an unfurled **antihelical** fold, a deep **conchal bowl**, or both. Many children are viciously teased by their peers because of their prominent ears. Surgical correction of the ears is a relatively simple and very satisfying operation. Interestingly, many third-party payers feel this is “cosmetic” surgery and refuse to pay for it. They seem to ignore the tremendous difference between the person who looks normal and wants to look better (cosmetic surgery) and the person who looks abnormal and wants to look normal (reconstructive surgery).

QUESTIONS

1. The most important part of any rhinoplasty is maintaining or improving the _____.
2. The first principle in the management of soft-tissue wounds is _____.

ANSWERS

1. Airway
2. Meticulous reapproximation

Salivary Gland Disease

A discussion of salivary glands should consider both **the major** (parotid, submandibular, and sublingual) salivary glands and **the minor** salivary glands. It is estimated that normal individuals have **750–1,000 minor salivary glands located submucosally** from the lips to the trachea.

Bilateral salivary gland enlargement is commonly caused by viral infections, including human immunodeficiency virus (HIV) and mumps. In addition, patients with autoimmune disorders may have salivary dysfunction (dry mouth), dry eyes, and arthritis. A cluster syndrome known as Sjögren's disease is frequently associated with parotid enlargement. Diagnosis is based not only on history and physical, but also on **serologic studies (SSA and SSB)**.

Bacterial parotitis is almost always caused by *Staphylococcus aureus*, and presents with all the classic signs and symptoms of infection, including **tumor (swelling), dolor (pain), calor (heat), and rubor (redness)**. Often, pus can be expressed from **Stensen's duct**. A potential cause is a salivary stone, although frequently the etiology is dehydration. Patients with bacterial parotitis generally do well when treated with hydration and antibiotics. Local applications of heat and **sialagogues**, such as lemon drops, are ancillary measures. Occasionally, the gland will need to be drained surgically.

Salivary gland stones (sialolithiasis) most commonly occur in the submandibular duct. They are usually **radio-opaque** and can occasionally be palpated by bimanual exam at the orifice of the duct adjacent to the **lingual frenulum**. Salivary gland stones can cause obstruction leading to **stasis with possible secondary bacterial infection**. Treatment is removal of the stone. The duct must be incised because the stone cannot be milked out distally. Some institutions are using salivary endoscopy and lithotripsy to treat salivary stones.

Masses often present in the salivary glands and need to be evaluated by an otolaryngologist. Physicians often perform fine-needle aspiration to

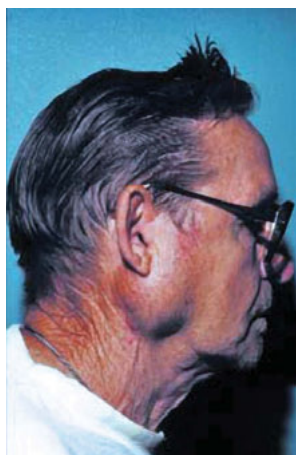

Figure 14.1.

Right parotid mass. Eighty percent of parotid neoplasms are benign, pleomorphic adenomas. However, 20 percent are malignant. Diagnosis can often be made by a fine-needle aspiration of the mass. Excision of benign tumors requires superficial parotidectomy and facial nerve dissection.

determine whether a malignancy is present. In general, any lump in front of or below the ear must be considered a parotid mass until proven otherwise. The parotid gland has a large amount of lymphoid tissue, to which the lymphatics on the side of the head drain. The most common metastatic lesion to the parotid gland is squamous cell carcinoma, generally a metastasis from a skin cancer on the side of the head. Malignant melanoma on the ear or scalp also metastasizes to the lymph nodes in the parotid. There are a variety of diagnostic studies that can be performed. Physical exam, radiographic imaging, and fine-needle aspiration are adequate for diagnosing 95 percent of parotid masses. However, surgical removal with superficial

parotidectomy remains the final diagnostic step of choice.

Parotid masses are usually resected with a superficial parotidectomy for two reasons. First, it is quite easy to damage the facial nerve branches, unless it is traced from its origin through its entire course in the gland. Second, the most common kinds of salivary tumors tend to recur, and this procedure allows the surgeon to get a good margin of tissue around the tumor and achieve a decreased recurrence rate. It is important that masses in this region not be **enucleated**, because injudicious excision can result in both facial nerve injury and recurrent tumor. Total parotidectomy, with preservation of the facial nerve, removes both the superficial and the deep lobes of the parotid, and may be required in some conditions. If cancer has invaded the facial nerve, sacrifice of the nerve may be required.

A Few Basic Principles about Salivary Gland Tumors

The larger the salivary gland, the less likely the tumor is to be malignant. Thus, a mass in the parotid has only a 20 percent chance of being a malignant tumor, a mass in the submandibular gland has a 50 percent chance, and a mass in the sublingual gland has a 75 percent chance. The most common benign tumor of the salivary glands is a **pleomorphic adenoma (mixed tumor)**. The most common malignant tumors are **adenoid cystic carcinoma** and **mucoepidermoid carcinoma**. Adenoid cystic carcinoma has a strong pro-

ensity to invade nerves and track along them. This is significant, because the seventh cranial nerve tracks right through the parotid gland. The lingual and hypoglossal nerves are very near the submandibular gland.

CHAPTER 14

QUESTIONS

1. The four classic signs and symptoms of an infection are _____, _____, _____, and _____.
2. Bacterial parotitis is most commonly caused by _____.
3. A lump in front of or below the ear is to be considered a _____ until proven otherwise.
4. The most common tumor in the parotid gland is benign and is a _____.
5. Treatment of most parotid tumors includes _____ with dissection and preservation of the facial nerve.

ANSWERS

1. Pain (dolor), swelling (tumor), redness (rubor), heat (calor)
2. *S. aureus*
3. Parotid mass
4. Pleomorphic adenoma
5. Superficial parotidectomy

Thyroid Cancer

Thyroid Nodules and Cancer

Thyroid cancer and the management of thyroid masses can be a confusing topic of discussion. **Thyroid nodules** are singular or multiple, often encapsulated, growths found on the thyroid gland. They are most frequently benign and so common, particularly with advancing age, as to preclude biopsy and removal in every patient who presents with nodules. However, otolaryngologists often recommend and perform removal of nodules that have a reasonable risk of being cancerous, as determined by multiple factors that include those discussed below.

Risk factors for malignant thyroid nodules are based on gender, age, early radiation exposure, and family history of thyroid cancer. While thyroid nodules are much more common in women than in men, a nodule in a male has a higher risk of being cancerous than a nodule in a female. Older people also develop more benign nodules than younger people (i.e., a nodule in a person younger than 40 years old has a higher chance of being cancerous than a nodule in a person over 40). In addition, larger nodules and nodules that demonstrate growth are more commonly malignant.

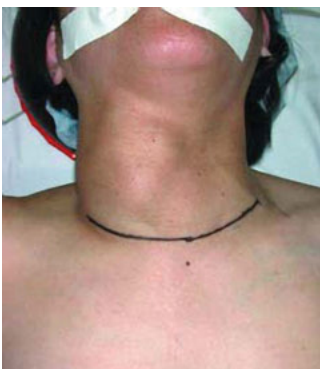

Figure 15.1.

Large neck mass eccentrically located in the right neck.

The standard accepted and effective method for determination of the contents of a thyroid mass or nodules is fine-needle aspiration biopsy (FNAB). This may be performed with or without ultrasound guidance, depending on the size and location of the lesion. While cytopathologic interpretation has improved, a clear diagnosis for malignancy is not always achieved. Reports, such as “indeterminant,” “suspicious,” or “noninformative,” are frequently tendered to the surgeon or endocrinologist, making the

decision for resection more challenging. An FNAB diagnosis of malignant cells, however, is an obvious indication for surgery, either a total thyroid lobectomy or a total thyroidectomy. Certainly, any evidence of thyroid cancer in the neck nodes is an indication for total thyroidectomy and appropriate neck dissection.

Remember, that absent any risk factors, there is a high degree of probability that the nodule is benign. If the pathologic interpretation on the FNAB favors a benign histopathology and the patient does not have any other risk factors for thyroid cancer, one can advocate observation. If the lab report is indeterminant or inconclusive, a repeat FNAB with the aid of an ultrasound is necessary to ensure sampling efficiency of the tissue. When multiple nodules are found, the thyroid is classified as a **multinodular thyroid or goiter**, and only the dominant or largest nodules are biopsied. If a single nodule is determined to be inconclusive by FNAB, FNAB should be repeated. Radionuclide **thyroid scans** have become less essential to the diagnostic workup of nodules with the development and refinement of ultrasound and fine-needle aspiration techniques.

Forms of Thyroid Cancer

There are two essential classifications of thyroid cancer: well differentiated and other. **The more common forms of thyroid cancer are well differentiated, and include papillary and follicular** (including the **Hürthle cell** variant). The “other” category includes less well-differentiated forms of thyroid cancer, including **medullary**, and **anaplastic**. **Lymphoma may also arise in the thyroid.**

Papillary Carcinoma

Approximately 80 percent of thyroid cancers are papillary histologically. These may have a **follicular component**, but any amount of papillary component means the tumor will behave more like a papillary tumor. These tumors **can be multifocal** in the gland and **often metastasize** to neck lymph nodes. The presence of lymph node masses does not appear to affect survival rates. Histologically, they have **clear nuclei** (“Orphan Annie” **cells**), and may have **psammoma** bodies. Factors predictive of a better prognosis include small size (less than 1.5 centimeters (cm)) and absence of thyroid gland capsule involvement. For unknown reasons, this disease follows a much more indolent course when discovered in people under age 40. However, while papillary carcinoma patients under 40 years of age ultimately live longer, they also experience a higher rate of recurrence.

Treatment of papillary carcinoma is somewhat controversial. Historically, a total thyroid **lobectomy** and **isthmectomy** have been used to treat smaller papillary thyroid cancers (<1 cm). More recently, the trend has been toward total thyroidectomy in patients with nodules containing papillary thyroid cancers. Newer evidence from a study by Mazzaferri and colleagues suggests that **total thyroidectomy**, when compared to subtotal, may significantly decrease the local recurrence rate (18% versus 7%), and ultimately the number of deaths (from 1.5% to 0.03%).¹ This study also points out that patients treated with **radioactive iodine** and **thyroid hormone suppression** have a decreased incidence of recurrence (3%), compared to those treated with thyroid suppression alone (11%). However, there was no difference in the number of deaths between these two groups.

As mentioned earlier, if cervical metastatic thyroid cancer is present, a **modified or selective neck dissection** is indicated, depending on the location of the disease. The greatest risks of thyroid surgery are hypoparathyroidism secondary to injury or removal of the parathyroid glands, and **recurrent laryngeal nerve injury**, which may result in hoarseness, shortness of breath, and reduced exercise tolerance.

Follicular Carcinoma

Approximately 15 percent of thyroid cancers is the follicular cell type. The surgical specimen of all thyroid cancers must be sectioned completely to determine if the tumor capsule and/or lymphatic and blood vessels are invaded. The findings of capsular and/or lymphovascular invasion are **essential for diagnosis** and cannot be determined by a fine-needle aspirate. Cytopathologically, the cells may also look fairly benign on fine-needle aspirate, so many specimens are interpreted as “consistent with adenoma, cannot rule out follicular carcinoma.” This tumor metastasizes via the blood. Two major types of follicular carcinoma are **microinvasive** and **macroinvasive**. A variant is Hürthle cell carcinoma, which is a more aggressive form of follicular thyroid cancer and is marked by a high frequency (75% or more) of Hürthle cells.

Like papillary carcinoma, follicular carcinoma has an affinity for radioactive iodine. Since iodine is concentrated in normal thyroid tissue, an attempt to remove all thyroid tissue allows a higher dose to be delivered to

¹ Mazzaferri, E.T., et al. A vision for the surgical management of papillary thyroid carcinoma: extensive lymph node compartmental dissections and selective use of radioiodine. *Journal of Clinical Endocrinology & Metabolism* 2009 Apr; 94(4):1086-1088.

the remaining tissue, thus reducing the necessary dose. Therefore, total thyroidectomy is the treatment of choice for follicular thyroid cancer. Multifocal disease is less commonly seen in follicular carcinoma. Post-operative treatment includes radioactive iodine and thyroid suppression.

Medullary Carcinoma

Medullary carcinoma accounts for 6–10 percent of all thyroid cancers. There are **two forms: familial (10–20%) and sporadic**. In either case, the **parafollicular or C-cells** are the cells of origin, and the tumor tends to be bilateral.

The familial form is a component of multiple endocrine neoplasms (MEN) IIa and IIb. MEN IIa involves **parathyroid adenoma**, medullary carcinoma, and **pheochromocytoma**. MEN IIb does not have a parathyroid component, but includes a **Marfanoid habitus** and mucosal neuromas. All patients with medullary carcinoma should get a urinary **metanephrine** screen to determine whether there is an increase in circulating catecholamines. If this test is positive, the pheochromocytoma should be located and excised first. All **first-degree relatives** of patients with medullary carcinoma should be tested for **calcitonin levels**. **Currently, it has been demonstrated that the RET proto-oncogene is positive in most patients with this disease. This oncogene can be detected by a blood test.**

Surgical management of medullary thyroid cancer is somewhat contentious. However, most surgeons elect to perform a total thyroidectomy with paratracheal, central compartment neck dissections. In patients with a neck mass, a modified neck dissection that encompasses all the involved levels of disease should be performed. In patients with the familial form, only abnormal parathyroid glands should be removed, but a total thyroidectomy is always indicated. Thyroid C-cells do not absorb radioactive iodine, so this common modality of adjuvant treatment in well-differentiated thyroid cancers is seldom effective.

Anaplastic Carcinoma

Anaplastic thyroid cancer is a rare, aggressive cancer with a very poor prognosis. The role of the surgeon is often limited to establishing diagnosis through open biopsy and securing the airway, which usually involves a tracheotomy. These tumors are rarely resectable, and are often treated with external beam radiation and systemic chemotherapy, since 50 percent of patients will have pulmonary metastases at the time of diagnosis.

Lymphoma

Thyroid lymphoma is a rapidly growing tumor, which frequently compromises the airway and clinically resembles anaplastic carcinoma. Lymphomas may arise in patients with a background of Hashimoto's thyroiditis, an autoimmune condition characterized by lymphocytic infiltration, but that's a very uncommon correlation. Thyroid lymphomas are most commonly B-cell. A rapid diagnosis and institution of appropriate therapy are necessary to prevent airway obstruction. Treatment and cure are usually achieved by using a combination of chemotherapy and radiation.

This brief discussion on thyroid cancer does not include a discourse on surgery of the thyroid gland. This would include such subjects as surgery for hyperthyroidism, which can occur with a toxic nodular goiter and Graves' disease. These conditions can also be treated medically using radioactive iodine-131, but further discussion is beyond the scope of this book.

QUESTIONS

1. The most common type of thyroid cancer is _____.
2. The second most common type of thyroid cancer is _____.
3. The treatment of follicular cancer involves surgery plus _____.
4. Patients with medullary carcinoma should have a urinary _____ screen.
5. The thyroid malignancy with the worst prognosis is _____ carcinoma.
6. The first step in the diagnostic evaluation of a thyroid nodule after the history and physical is usually _____.

ANSWERS

1. Papillary
2. Follicular
3. Radioactive iodine
4. Metanephrine
5. Anaplastic
6. Fine-needle aspiration

Head and Neck Cancer

Diagnosis and management of head and neck cancer is a broad topic. In this chapter we will provide background information about the disease, information on diagnosis and management, and a few case studies. These will help you understand how to integrate information and treatment modalities to affect a successful, modern approach to head and neck cancer.

Head and neck cancer primarily refers to carcinomas of the larynx; naso-, oro-, and hypopharynxes; paranasal sinuses; salivary glands; and oral cavity. Historically, the majority of these cancers occurred in patients with a history of smoking and alcohol use, and were squamous cell carcinomas of the upper aerodigestive tract. While this is still true, the incidence of oropharyngeal cancers is increasing, primarily due to HPV-mediated cancers.

Almost all (95%) head and neck cancer is squamous cell carcinoma. The cancer originates from the **cuboidal cells** along the basement membrane of the mucosa. Under the microscope, the cancerous cells appear flat, so the cancer is called squamous (from the Latin *squama*, “a scale or platelike structure”) cell carcinoma.

Figure 16.1 is a common presentation of a head and neck cancer. An adult patient with a persistent lump in the neck is very likely to have a malignant process, with its origins in the upper aerodigestive tract. A single course of antibiotics is warranted, but preparation should be made for immediate consultation with an otolaryngologist–head and neck surgeon, as there is a high likelihood that this represents a neoplasm.

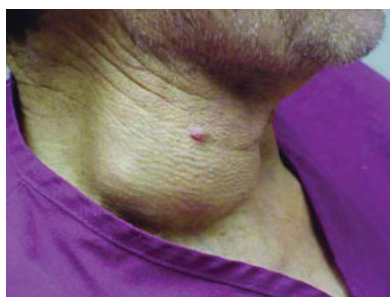

Figure 16.1.

Neck mass in an adult patient with squamous cell carcinoma of the hypopharynx who presented to the primary care physician with a large, firm neck mass. Needle aspiration confirmed the diagnosis of squamous cell carcinoma.

Many different approaches to the evaluation of this tumor have been utilized in the past. Often a physician would perform an open biopsy of the lump in the patient's neck, and discover that it was squamous cell carcinoma. The fact is that this neck mass represents a metastatic node from the upper aerodigestive tract, in this particular case the **pyriform sinus of the hypopharynx**.

However, the more modern approach for this type of lesion is a fine-needle aspirate biopsy of the neck mass in the clinic following a complete head and neck exam. A CT scan of the neck and chest and possible positron emission tomography (PET) scan for complete staging and treatment planning should be ordered. The patient may be taken to the operating room for “panendoscopy” (i.e., laryngoscopy, esophagoscopy, bronchoscopy), although imaging has all but erased the need for intraoperative bronchoscopy as a screening tool.

Hoarseness

Patients who have been hoarse for more than two weeks should also be referred to an otolaryngologist for laryngeal examination. The most common cause of hoarseness is a URI with edema (swelling) of the true vocal cords. This often lasts several weeks, but it rarely lasts six weeks. Six weeks of hoarseness in an adult is very suspicious for a precancerous (dysplasia) or cancerous lesion of the larynx. If the lesion is not cancerous, other causes of hoarseness may include inflammation from **gastroesophageal reflux disorder (GERD)**, also known as **laryngopharyngeal reflux**, allergic rhinitis causing postnasal drip, **laryngeal papillomatosis**, vocal cord nodules, vocal cord polyps, and **unilateral vocal cord paralysis**.

Otalgia

A patient who has cancer may also present to a primary care physician with pain in the throat or pain in the ear (**otalgia**) that has no obvious cause. The oropharynx and hypopharynx are innervated by the ninth and tenth cranial nerves. These also send branches to the ear, and sometimes a cancer in the throat can generate referred pain to the ear. The oral tongue is served by the lingual nerve (fifth cranial nerve), and may cause jaw pain and otalgia as well. If a patient comes in with ear pain and the ear looks normal to you, it probably is normal and the pain is probably being caused by some other otolaryngologic problem.

The most common cause of ear pain with a normal ear exam is **temporomandibular joint syndrome (TMJ)**. This inflammation of the joint of the jaw can be diagnosed by pain on palpation of the joint (just in front of the

tragus) when the patient opens and closes the jaw. If the joint is not tender and there is no other obvious cause of ear pain, the patient needs further evaluation. Difficulty in swallowing (**dysphagia**), pain on swallowing (**odynophagia**), or a **persistent oral ulcer** may be due to cancer. Patients with these symptoms should see an otolaryngologist. Sometimes a cancer in the nasopharynx can obstruct one of the eustachian tubes, causing **unilateral serous otitis media (fluid in middle ear) in an adult**. The most common cause of this condition is a URI, but a unilateral serous otitis without a clear history of a cold must be referred for nasopharyngoscopy.

Occasionally, patients will present with a superficial lymph node located in the posterior triangle of the neck (behind the **sternocleidomastoid muscle**). Most commonly, this is a swollen lymph node secondary to some type of skin infection or inflammation on the scalp, so you should check the scalp carefully in such a case. Sometimes, however, this can be something as serious as a lymphoma. Usually, upper aerodigestive tract squamous cell carcinoma does not initially spread to the posterior triangle nodes, but in rare cases, this can occur—especially with nasopharyngeal cancer. Physicians can be tempted to remove this superficial node of the neck in the office. However, these superficial posterior neck nodes should not be surgically addressed, except by someone very familiar with head and neck surgery. The **spinal accessory nerve** runs over the top of these nodes and can very easily be damaged if the physician is not experienced with this kind of surgery.

Parotid Mass

You may also encounter a lump in front of or below the ear. This most often represents a parotid neoplasia, the most common of which is the benign mixed tumor (pleomorphic adenoma). A mass in this area, however, can be something as superficial as an **epidermal inclusion cyst**, or something more serious, such as lymphoma. The problem with this particular area is that it is quite difficult to distinguish between something that is merely subcutaneous and something that is in the parotid gland. The **ascending ramus of the mandible** is deep to the parotid gland; thus, a mass may be well within the substance of the gland and still feel very superficial, because there is a solid background immediately behind it. Well-intentioned surgeons, thinking this is a sebaceous cyst, have ventured into removing one of these lumps, and have found they unexpectedly need to go deep to the parotid fascia. If you ever find yourself in this position, you should recognize this situation for what it is, and appropriately cease further dissection. This is not the time for surgical heroics—remember the facial nerve! In situations such as this, it is better to refer the patient to an otolaryngologist.

As your sixth-grade teacher used to say, “Let’s review.” Since most physicians are in some type of primary care specialty, it is important to know when to refer a patient to a specialist in diseases of the head and neck for any symptoms that suggest the **possibility of cancer**:

- A mass in the neck
- Hoarseness for two weeks or more
- Pain in the ear (otalgia), pain in the throat on swallowing (odynophagia), or difficulty swallowing (dysphagia)
- A lump below or in front of the ear
- A persistent oral ulcer
- Unilateral serous otitis media

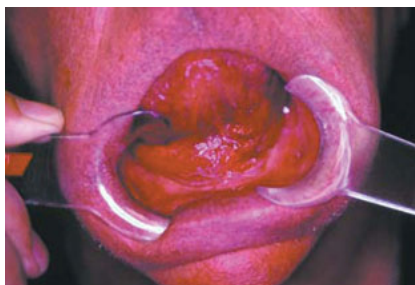

Figure 16.2.

Carcinoma of the floor of the mouth. Mucosal tumors of the upper aerodigestive tract are almost always squamous cell cancer, and occur as a result of exposure to tobacco and alcohol. Unfortunately, tumors are often discovered late, making treatment more complex.

Cancer occurs most often in the fourth to seventh decade of life in people who have been exposed chronically to carcinogens and irritants found in cigarette smoke and alcohol. These carcinogenic agents act in a **synergistic manner**—that is, each promotes the occurrence of the cancer, but the combined effect is greater than the sum of the two. It follows that if a person gets one cancer, he or she may get another one in a different part of the upper aerodigestive tract (esophagus and lungs). Indeed, additional cancers are found in 10–20 percent of the patients who present with head and neck cancer.

Endoscopy

Once a suspicious lump has been identified, a full ENT exam should be performed, in addition to a fiberoptic or formal endoscopy in the operating room. There are three main reasons to use endoscopy in these cases. The first is that it allows the physician to evaluate the size and extent of the primary tumor (the original mucosal tumor, the source of the metastases likely to be found in the neck). Many patients present with a mass in the neck, and you will need to use endoscopy to locate the primary tumor. Sometimes the primary tumor is very small, while the neck metastasis is

very large. About 10 percent of the time, the primary head and neck tumor cannot be found—this is called “**carcinoma of unknown primary.**” A second reason to perform endoscopy is to look for **second primaries, which may occur anywhere along the upper aerodigestive tract.**

The third reason to use endoscopy is to take a small piece of tissue with biopsy forceps and obtain a tissue diagnosis. Otolaryngologists use **rigid endoscopes** more than other specialists do, because they make it easier to get a good biopsy specimen. Rigid endoscopy is usually performed under general anesthesia for better patient relaxation and comfort. If the tumor is in the oral cavity, base of the tongue, or oral pharynx, it is palpated as well. The procedure usually takes less than an hour, and the patient may go home the same day. Overnight observation may be necessary if the patient has advanced cancer of the larynx, and there is a risk that the swelling caused by the procedure may obstruct the already compromised airway.

One proviso: In the modern evaluation and treatment planning of head and neck cancers, diagnostic imaging (e.g., CT, MRI, PET, ultrasound), in-office endoscopy, and the use of FNAB may obviate the need for endoscopy under anesthesia. In many cases diagnostic imaging is conducted because it provides important information about the depth and extent of the tumor that cannot be appreciated otherwise.

Diagnosis and Treatment

Once the patient has been “scoped,” what do you do next? Remember that endoscopy is used to evaluate the size of the tumor, including estimation of the third dimension (depth). In general, T1 cancers measure less than two centimeters (cm), T2 cancers are two to four cm, T3 are larger than four cm, and T4 are large, invasive tumors involving vital structures with no clear

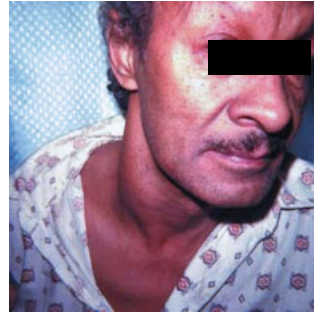

Figure 16.3.

Mass occurring in mid-portion of right neck in a man with a past history of tobacco usage. This most likely represents metastatic squamous cell cancer from a primary site somewhere in the upper aerodigestive tract. Diagnostic workup includes head and neck examination, CT scan imaging, and fine-needle aspiration biopsy.

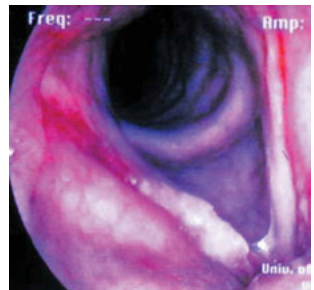

Figure 16.4.

Early squamous cell cancer of the vocal cord arising in a smoker. This patient presented with voice change and hoarseness. Early detection and appropriate treatment provide the greatest opportunity for cure in these individuals.

margination in the soft tissues of the neck. Cancer of the larynx, particularly glottic cancer, is usually smaller at presentation because of the relatively quick onset of symptoms, and a different staging system is used. Small or early tumors without metastases do well, and large or metastatic tumors do poorly. Unfortunately, however, 60–75 percent of patients do not present until the tumor is large or metastatic.

In general, T1 and T2 cancers respond well to surgery or radiation therapy (75–80%, five-year survival). For larger or metastatic lesions, surgery and radiation therapy are usually recommended, and the prognosis is poorer (15–35%, five-year survival). In addition, chemotherapy potentiates the effects of irradiation, and has become an important adjunct in the treatment of head and neck cancer.

When head and neck cancer patients receive radiation therapy as part of their treatment, it is usually given once a day for six weeks, although some physicians use twice-a-day protocols. It is generally felt that 5600 rads centigray (cGy) is a minimum dose for a neck with microscopic disease. If there is a big, bulky tumor somewhere, the dose may go up to 7000–8000 cGy. Radioactive implants using a cesium source (**brachytherapy**) may be placed to deliver a very high, localized dose to a superficial tumor. There are acute and late effects of radiation therapy, which cause mucositis and xerostomia by way of destruction of the major and minor salivary glands' ability to produce salivary secretion. Since teeth remineralize with the minerals in saliva, they are very prone to decay during and after this therapy. If a patient has teeth in very poor condition, all the teeth are extracted before the patient begins radiation therapy.

Metastasis

Squamous cell carcinoma tends to metastasize early, first to the lymph nodes of the neck and then to the lung, liver, bone, and brain. A chest x-ray, or more often a CT scan of the chest, should be obtained to be certain the patient has neither metastasis nor a second tumor (which is more likely) in the lung. If the tumor has metastasized to the lungs or liver, the role of surgery is limited to palliation. However, the lungs are infrequently involved with metastatic disease at the time of initial diagnosis. If the metastases are confined to the lymph nodes of the neck (the most common scenario), then a neck dissection—removing lymph nodes from the neck—is performed at the time of surgery. The lymph nodes are nestled in fat and wrapped in fascia. **Selective neck dissection** involves removing only nodes, fat, and fascia most likely involved by metastasis. A **radical**

neck dissection is performed when bulky metastasis demands radical surgery and includes **removal of the sternocleidomastoid muscle, internal jugular vein, and spinal accessory nerve**. For more on neck dissection, see the free AAO-HNSF e-book *TNM Staging of Head and Neck Cancer and Neck Dissection Classification* (<http://www.entnet.org/mktplace/NeckDissection.cfm>).

QUESTIONS

1. The most common histopathologic diagnosis for cancer of the upper aerodigestive tract is _____.
2. Cigarette smoke and alcohol work in a _____ manner to promote cancer.
3. People who have one cancer of the upper aerodigestive tract may have another primary malignancy in the upper aerodigestive tract. This is called synchronous primary, which is one of the reasons why _____ is performed.
4. Taking a biopsy and evaluation of the actual size of a tumor are two other reasons why _____ is performed before final treatment of a head and neck cancer.
5. Small head and neck cancers can often be treated with either _____ or _____.
6. Large head and neck cancers are often treated with _____, _____, and _____.
7. Squamous cell carcinoma of the head and neck usually metastasizes to the lymph nodes in the _____ before going to other sites.
8. A radical neck dissection (RND) involves removing the sternocleidomastoid muscle, the spinal accessory nerve, and the _____, which are intimately related to the lymphatic structures of the neck.
9. Radiation therapy dries up the _____ glands.
10. A mass in the neck may be a _____ from a cancer somewhere in the upper aerodigestive tract.
11. A patient who is hoarse for more than two weeks may have _____ of the larynx.
12. A patient with a lump below or in front of the ear may have a tumor of the _____ gland and needs to see an otolaryngologist.
13. A persistent oral ____ may be the first sign of a cancer.

14. When there is a normal ear exam, _____ may be caused by a cancer in the pharynx.
15. Persistent unilateral serous otitis media may be caused by a cancer in the nasopharynx obstructing the _____.
16. Parotid masses feel superficial, because the parotid gland is immediately superficial to the _____ of the mandible.

ANSWERS

1. Squamous cell carcinoma
2. Synergistic
3. Triple endoscopy
4. Endoscopy
5. Surgery, radiation therapy
6. Surgery, radiation therapy, chemotherapy
7. Neck
8. Jugular vein
9. Salivary
10. Metastasis
11. Cancer
12. Parotid
13. Ulcer
14. Otagia
15. Eustachian tube
16. Ascending ramus

Skin Cancer

The great majority of skin cancers arising on the skin of the face, scalp, and neck are **basal cell carcinoma**, followed by squamous cell carcinoma, then **malignant melanoma**. Basal cell carcinoma is very common and most often occurs on the face, so the otolaryngologist–facial plastic surgeon sees many cases.

The typical basal cell carcinoma is a **nodular lesion with a raised, pearly-white border**. These lesions are usually brought to the physicians' attention before they become very large. They do not metastasize and can be treated in a variety of ways. Dermatologists may freeze or curette them. When the patient is referred to an otolaryngologist–head and neck surgeon, the lesions are usually excised with a three- to four-mm margin, followed by a meticulous closure of the defect, which occasionally requires a rotation or advancement flap from the neighboring skin. These flaps restore cosmetic integrity to the facial unit affected by the tumor.

Another approach to resecting basal cell and some squamous cell cancers involves **Mohs' fresh tissue chemosurgery technique**. This technique requires tumor mapping: using small, sequential tumor resection in layers with immediate pathologic examination under a microscope to ensure complete removal. This technique takes significantly longer than any of the other methods, but the recurrence rate can be lower. For this reason, certain tumors with a higher-than-usual chance of recurrence with conventional excisions may be better managed with Mohs' surgery. It is also performed **near cosmetically and functionally sensitive structures**, such as the eyelids, nose, and ears, in order to preserve as

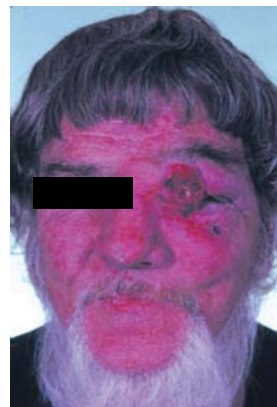

Figure 17.1.

Very large **basal cell carcinoma** of the facial skin. Note the rolled edges with central ulceration, indicating subepithelial extension. Excision must ensure that the tumor is completely removed or recurrence is highly likely.

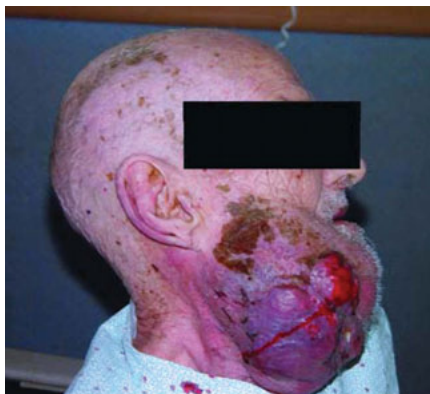

Figure 17.2.

A large neglected **squamous cell carcinoma** of the face is present in this individual.

much uninvolved tissue as possible. **Morpheaform basal cell carcinoma**, a **sub-type** of basal cell carcinoma, has very indistinct borders without the characteristic features of the nodular variant. It is very difficult to excise without the use of real-time, histologic feedback. Therefore, this type of basal cell carcinoma is ideally suited for Mohs' surgery. Unfortunately, Mohs' surgery is also costly.

Squamous cell carcinoma is more aggressive and may metastasize. It generally requires excision of a five- to six-mm margin to ensure complete removal. Metastasis often occurs in

the setting of deep-lesion ulceration and recurrent lesions. Evaluation of the neck nodes and careful follow-up to detect early recurrence or metastasis are necessary. Larger tumors are usually treated with wide excision and neck dissection to remove any possible metastases.

Malignant Melanoma

Cutaneous malignant melanoma is a capricious tumor that affects patients of all ages and has a high mortality rate. There is mounting evidence that sun exposure in childhood is a strong risk factor. It is very common in Australia, and public education in that country has led to the widespread frequent wearing of broad-brimmed hats and the use of sunscreen lotions among 50 percent of adults and children. Both adults and children should be protected from the sun when outside in the summer and in warmer climates. One important point to recognize is that melanomas of the head and neck often display different behavioral tendencies than those in other areas of the body.

Melanoma frequently presents as a **pigmented lesion, often a mole**, that has advanced through radial and vertical growth, color, margin integrity, ulceration, or bleeding. **Melanoma begins in the epidermis and then invades the dermis.** The depth of invasion is strongly predictive of risk of metastases and ultimately patient survival. The Breslow classification system includes thin (1-mm invasion or less), intermediate (greater than 1 mm and less than 4 mm), and thick (greater than 4 mm). The risk of metastatic disease is less than 10 percent with thin lesions but greater than 90

percent with thick ones. It is important that the primary physician and dermatologist remain vigilant for darkly pigmented moles and those that have changed, bleed, are raised, or have irregular margins. Early detection and excision are critical to patient outcomes.

The initial treatment of cutaneous melanomas after diagnosis and determination of depth is wide (2 cm) surgical resection and, when appropriate, sentinel node lymphoscintigraphy to determine the first echelon of the draining lymphatic basin and identification of nodes at the highest risk for metastatic involvement. Afterwards, parotidectomy, selective nodal dissection, bioimmunotherapy, and radiation may all be used to treat head and neck melanoma at some point in the patient's care.

QUESTIONS

1. The three most common types of skin cancer are _____, _____ and _____.
2. Most basal cell carcinomas are nodular in appearance, with very distinct borders, and are easily treatable. There is, however, a certain type that has very indistinct borders. This is called _____.
3. Certain basal cell carcinomas have a higher incidence of recurrence than others. These include _____, _____ and _____.
4. Some basal cell carcinomas may be very close to vital structures, such as the lower eyelid or the ala of the nose. In this case, maximum preservation of tissue is a consideration, and these patients are candidates for _____ surgery.
5. Squamous cell carcinoma of the face is aggressive and commonly metastasizes to the _____.
6. The metastatic potential of malignant melanoma depends on _____.
7. Signs of malignant melanoma are a mole that is _____, _____, _____, _____ or _____.

ANSWERS

1. Basal cell, squamous cell, malignant melanoma
2. Morpheaform carcinoma
3. Recurrent, large (greater than 2 cm), and morpheaform
4. Mohs'
5. Cervical lymph nodes
6. Tumor thickness
7. Darkly pigmented, raised, bleeding, changing, has irregular margins

Pediatric Otolaryngology

A high percentage of illnesses affecting children involve the ears, nose, and throat. Nearly all otolaryngologists treat children and some treat only children. An excellent library reference on pediatric otolaryngology is the two-volume text by Bluestone et al.¹ You should refer to it often during your pediatric rotation. The most common pediatric disorder seen by the otolaryngologist and pediatrician is **otitis media**, so it is important to understand the spectrum of this disease. This is presented in the Bluestone book in Chapter 5, Otitis Media.

Foreign Bodies in the Ear, Nose, and Throat

Let's face it: Children seem to have a propensity for putting things into just about any orifice possible. Thus, they will often place pebbles, erasers, small toys, etc., into their external auditory canal. Treating this problem is usually a fairly benign process that can be dealt with in a non-emergent manner, but the exception to the rule is if there is a strong possibility of damage to the middle or inner ear. If this has occurred, the child may have lost sensorineural hearing, and may also be dizzy. Another exception is if the foreign body is alive! It is important to kill insects in the ear canal (usually drowning in drops of olive oil is a good choice) before removal. These children should be referred immediately to an otolaryngologist.

Most commonly, the foreign body remains in the lateral part of the external auditory canal. Remember that these young patients often become uncooperative, and may require general anesthesia for the simple removal of the object, especially if prior attempts have been made to remove it. Therefore, unless certain, easy, nontraumatic, removal of the foreign body is completely assured, refer to an otolaryngologist.

Children also like to put foreign bodies in their nose. This invariably results in **unilateral, foul-smelling, purulent rhinorrhea**. Parents will

¹ Bluestone, C.D., M.A. Kenna, and S.E. Stool. 1996. *Pediatric Otolaryngology*. Philadelphia, PA: W.B. Saunders Company, 1677 pp.

often report that their child “smells bad.” The key here is that the rhinorrhea is on only one side. (If it were due to a cold or a sinus infection, it should be bilateral.) Occasionally, removal will require general anesthesia, but topical anesthesia and vasoconstrictive nose drops may shrink the swelling sufficiently to aid in removal.

You must be aware of the potential problems caused by button batteries, which can leak caustic fluid and result in serious burns. If lodged in the esophagus, they can cause fatal perforation with **mediastinitis**. Button batteries can cause severe burns and should be removed emergently to prevent or minimize long-term complications. Later in this chapter, we will more specifically discuss esophageal foreign bodies as a cause of stridor.

Tonsillectomy

In the pre-antibiotic era, the indication for a **tonsillectomy** was the presence of tonsils, as it was the only treatment available for recurrent infections. Now, otolaryngologists have refined patient selection and, for the most part, tonsillectomies are performed on adult and pediatric patients with recurrent or chronic tonsillitis, obstructive sleep apnea, asymmetric tonsils, and peritonsillar abscess. In adults and children, asymmetric tonsils may be an indication.

Recurrent Tonsillitis

Some children have several bouts of tonsillitis per year that require evaluation by a physician. In treating recurrent tonsillitis, you should obtain culture documentation of Group A, β hemolytic strep, and if possible, obtain documentation of infections treated at other locations.

The *Clinical Practice Guideline: Tonsillectomy in Children* recommends that tonsillectomy is indicated when children present with seven or more infections per year, five per year for the past two years, or three per year for the past three years.² If the recommended number of infections has not been documented, then watchful waiting is suggested. Mitigating factors include children with a history of recurrent severe infections requiring hospitalization; complications of infection, such as peritonsillar abscess, periodic fever, aphthous stomatitis, pharyngitis and adenitis (PFAPA) or Lemierre’s syndrome (thrombophlebitis of the internal jugular vein); multiple antibiotic allergy/intolerance; a family history of rheumatic heart disease; or numerous repeat infections in a single household (“ping-pong spread”). However, each patient is different, and the final decision should

² Baugh, R.F., et al. 2011. Clinical practice guideline: tonsillectomy in children. *Otol Head Neck Surg* 144:S1-S30.

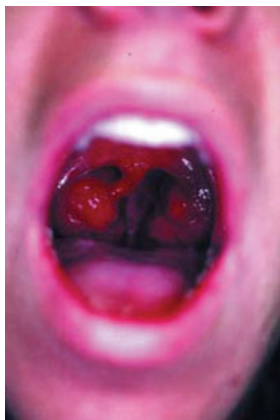

Figure 18.1.

Massive tonsil hypertrophy. Indications for tonsillectomy include recurrent episodes of tonsillitis or chronic upper airway obstruction resulting in sleep apnea. Enlargement without symptoms is not an indication for removal.

be an agreement between the patient or caregivers and the physician.

Chronic Tonsillitis

Chronic low-grade infection of the tonsils can occur in older children, adolescents, and adults. These patients often have large **crypts**, or spaces within the tonsils that collect food and **debris**, that are difficult to treat with antibiotics. The lymph nodes in the neck are usually inflamed from constant tonsillar infection. Sometimes, the retained food and debris lead to chronic halitosis (bad breath). The typical history from these patients is that their sore throat gets better on antibiotics, but then comes back as soon as they stop taking their medication.

Obstructive Sleep Disorders

Enlarged tonsils and adenoids are often the source of airway obstruction in children, and they result in sleep-disordered breathing. In adults, the site of obstruction usually occurs at multiple levels and

typically includes an increased amount of soft tissue in the pharynx and hypopharynx. **Daytime lethargy, obstructive symptoms, growth retardation, behavioral problems, including poor school performance and hyperactivity, and nocturnal enuresis** are often associated with the obstructive sleep disorder. In severe—although rare—cases, pulmonary or cardiac disease can result.

Diagnosis is usually straightforward, based on history and physical examination, although a recorded sleep tape is frequently used as collaborative evidence. In some instances, a formal sleep study may be required. If the diagnosis of obstruction is substantiated, tonsillectomy and adenoidectomy is often curative, although in some populations persistent or recurrent symptoms may occur. A particularly severe form of sleep apnea occurs in children with **Down syndrome**. Surgery on these children carries increased risk and requires specialized anesthetic care and a formal polysomnogram, prior to surgery. Young children less than three years of age with severe sleep apnea often require careful postoperative monitoring in the intensive care setting. Special perioperative management is indicated with morbidly obese children, children with craniofacial deformities, including clefts, and children with neuromuscular disorders.

Asymmetric Tonsils

Asymmetric tonsils are usually due to **recurrent scarring from infections**, but they may harbor tumors (such as lymphoma) and should be removed for **pathologic examination**. Asymmetric tonsils in children are usually more apparent than real, with asymmetry of the soft palate and anterior pillars or recurrent scarring from infections as factors in the apparent discrepancy. Malignancies rarely present as asymmetry in children. Careful assessment of the adult patient with tonsillar asymmetry is necessary to determine if a lymphoma or other malignancy is present and surgical intervention is warranted.

Peritonsillar Abscess

An abscess that collects in the potential **space between the pharyngeal constrictor and the tonsil** itself is termed a **peritonsillar abscess** or “quinsy.” These patients present with a history of recent sore throat that has now become significantly worse on one side. The classic signs of a peritonsillar abscess are **fullness of the anterior tonsillar pillar, deviated uvula**, “hot-potato voice” (somewhat muffled sound to voice), and severe **dysphagia**. Most of these patients also have **trismus (inability to open the jaw)** to some extent. Treatment is either aspiration with a large needle or incision and drainage done under local or general anesthesia. A one-inch incision is made in the superior part of the anterior tonsillar pillar. A hemostat is used to open up the incision into the peritonsillar space, and the abscess is drained. Usually, patients are hydrated, treated with appropriate high-dose antibiotic therapy, and sent home on oral antibiotics (assuming they can tolerate intake by mouth).

Some patients will suffer only one episode in their entire lives, but if a patient has two or more episodes, a tonsillectomy is usually recommended. In a child, general anesthesia may be necessary to drain the abscess. In these cases, you should consider performing a tonsillectomy at the same time, especially if there is a history of recurrent or chronic infections or airway obstructions. Many surgeons routinely prefer urgent tonsillectomy, because they feel it most effectively drains the abscess and prevents recurrence.

Adenoidectomy

The **adenoids** are **lymphoid tissue** situated on the posterior pharyngeal wall and roof of the nasopharynx, just behind the **soft palate** and adjacent to the **torus tubarius** (eustachian tube openings). When the adenoids are enlarged, symptoms of airway compromise arise, such as nasal obstruction, chronic mouth breathing, and snoring. **Adenoiditis** can result in

secondary eustachian tube dysfunction, and the proximity of a bacteria reservoir within the adenoid tissue can be an underlying cause of otitis media and sinusitis in children. Adenoidectomy is often performed in older children who have recurrent acute otitis media or chronic otitis media with effusion, especially if effusion has returned after tympanostomy tube extrusion. Tonsillectomy is often combined with adenoidectomy for children who snore loudly or have apnea with nasal obstruction. Adenoids usually atrophy with puberty, although they can remain enlarged into adulthood.

Stridor

Children are also commonly referred to the otolaryngologist for **stridor**, a high-pitched, noisy respiration emanating from the larynx or upper trachea that is a sign of respiratory obstruction. Stridor can be caused by a number of conditions, including several that can be life threatening: **acute epiglottitis**, **croup**, or **foreign body aspiration**.

Acute Epiglottitis

Acute epiglottitis is an infection of the supraglottic (above the vocal cords) structures that causes swelling of the portion of the larynx above the vocal cords. The swelling can become so severe that it blocks the airway. It is fulminant and usually caused by *Haemophilus influenzae* type B organisms. This fatal disease was common 20 years ago, but the incidence has decreased dramatically with widespread use of the *H. influenzae* (HiB) vaccine. The typical affected child is three to six years old and septic. Often, the child was breathing normally just hours earlier. The cardinal signs of acute epiglottitis are stridor, leaning forward in a tripod posture, and drooling because it hurts to swallow. If you suspect acute epiglottitis, immediately call an otolaryngologist, anesthetist, and pediatrician. Most pediatric hospitals have a specific protocol that automatically activates a team of airway experts once the diagnosis of acute epiglottitis is suspected.

Remember: If the child obstructs acutely, the airway can almost always be maintained with a bag and mask. Do not attempt to examine the child or force the child to lie back, because the agitation associated with the examination can precipitate sudden, complete obstruction. These cases are difficult and test the most skillful of anesthesiologists.

Every effort must be made to expedite rapid transport to the operating room with as little manipulation as possible. If there is a reasonable amount of doubt as to the diagnosis, an alternative is to have physicians from all three services accompany the patient to the radiology suite for a

lateral soft-tissue view of the neck. This is rarely done. Instead, physicians from all three services should accompany the child to the operating room, where he or she can be induced under anesthesia by masked induction with an inhalation agent and intubated. An IV can then be started and blood cultures obtained. Appropriate antibiotic therapy includes coverage for *H. influenzae* type B, as well as for the much more rare *Staphylococcus aureus* organisms, until final confirmation of the cause by blood cultures. Appropriate double-drug therapy would be ceftriaxone and oxacillin. Appropriate single-drug therapy would be cefuroxime, which can be continued by mouth later. The patient is usually extubated within 48–72 hours after confirmation of resolution by laryngoscopy.

Croup

Although both are forms of acute upper-airway obstruction in children, croup should be **distinguished** from acute epiglottitis because the management is different. Croup is the common name for **laryngotracheobronchitis**, a **viral infection of the upper airway** causing swelling in the subglottic (below the vocal cords) area and stridor. It usually occurs in children three–six months to three years old who have had a prodromal URI, usually for about a week. Patients are not septic, but may have a low-grade fever. The stridor is high pitched, biphasic (with both inspiration and expiration), and associated with a “barking” cough—often sounding like a seal. It does not hurt to swallow, so the patient is not drooling and the epiglottitis is not swollen, so the patient is not always leaning forward. The classic radiographic finding is the “steeple sign,” showing subglottic narrowing on a chest or neck **x-ray**. The treatment for croup is **humidity, oxygen, and, if necessary, racemic epinephrine treatments or steroids, or both**. Antibiotic therapy may be used if bacterial superinfection is suspected. If croup is severe, the child should be admitted to the hospital for observation. Intubation is rarely required.

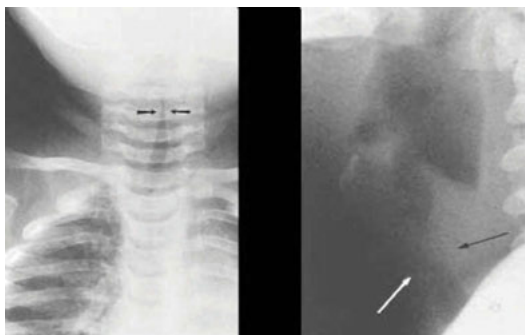


Figure 18.2.

This radiograph demonstrates “steeple sign” narrowing of the trachea in a young child with croup. See arrow.

Rarely, children with subglottic stenosis will present with “recurrent croup.” In these children, evaluation by an otolaryngologist, including direct laryngoscopy, is required.

Foreign Bodies

Foreign bodies can be another cause of stridor in children. Most commonly, stridor is caused by a foreign body that has been aspirated into the tracheo-bronchial tree—anything from coins to peanuts to Christmas tree light bulbs. (Advise parents to make sure that small children are not allowed access to small toy parts, peanuts, raw carrot pieces, and other things of similar size.) Foreign bodies in the airway often prompt paroxysmal coughing and stridor that may or may not resolve, followed by wheezing. It is critical that your diagnosis not be confused with asthma, although new-onset asthma may be difficult to distinguish. Occasionally, there can be a symptom-free period after initial aspiration. The most specific and sensitive aspect to the workup of a child with a suspected foreign body is a history of a choking event. If this is present, an airway foreign body must remain at the top of the differential diagnosis, until ruled out, usually by laryngoscopy and bronchoscopy.

Small objects swallowed by children can also lodge in the hypopharynx or esophagus. Occasionally, the child will refuse to drink anything and may present with drooling. Sometimes, the patient will not eat, but will drink. In these cases, an x-ray is usually obtained and, under general anesthesia, a **rigid esophagoscope** is used to remove the foreign body from the esophagus. If the foreign body has been aspirated, then bronchoscopy is required. A problem with the aspiration of peanuts (which seems to be quite common) is that the oil and salt produce a chemical inflammation that causes the bronchial mucosa to swell, making removal difficult. Do not forget that a child may present with recurrent bouts of pneumonia, and this can be due to an aspirated foreign body that was not detected at the time of aspiration. Occasionally, bronchial ball valve obstruction will result in hyperinflation of one lung, which is visible on a chest x-ray and more evident with lateral decubitus views.

Subglottic Stenosis

With the advent of modern neonatal intensive care, acquired **subglottic stenosis** has become an increasingly common cause of stridor. It is most commonly caused by scarring from long-term placement of an endotracheal tube. Neonates seem to tolerate extended endotracheal intubation better than adults. However, after weeks and months of intubation, some of these patients may develop scarring in the subglottic area that causes a

narrowing of the airway. This can occur acutely or over the course of several months after extubation. These patients present with stridor, which may be **biphasic** because it is due to a fixed obstruction in the larynx (children with subglottic stenosis are sometimes erroneously diagnosed as having asthma). In more mild cases, children with underlying subglottic stenosis may present with recurrent croup, as mentioned above.

If the subglottic stenosis is severe, there are several treatment options. The first option is to place a tracheotomy to bypass the obstruction. There are many problems associated with tracheotomy in infants, including delays in speech development, chronic mucous plugging, and even risk of death due to an obstructed tube. One solution is to surgically enlarge the airway with a **cricoid split**. This can include simply making a vertical incision in the anterior cricoid ring, allowing it to expand while an endotracheal tube remains in the airway for a week to 10 days. This particular procedure is not used as frequently today. Instead, the expansion may be supported by transferring a small strip of cartilage harvested from the thyroid ala and secured into the incision of the cricoid. If this is inadequate and the child still has some stenosis, a formal **laryngotracheal reconstruction** can be performed, in which rib cartilage is grafted into the cricoid cartilage and upper tracheal rings to allow for a more dramatic expansion. The airway expansion can be stabilized with use of a stent (tube secured within the airway at the site of reconstruction) for varying lengths of time. The success rate for this procedure is good, but is inversely proportional to the extent of the original degree of stenosis. Another way of treating mild stenosis involves using a laser to incise the involved area, followed by balloon dilation.

Subglottic Hemangioma

Another cause of stridor in children can be a **subglottic hemangioma**. Often stridor presents within the two- to four-month age range, when hemangiomas go through a characteristic rapid growth phase. Classically, 50 percent of these patients will have other associated head and neck hemangiomas, which will be visible on the skin. In some situations, these hemangiomas can be treated with a laser. Systemic steroids and interferon may play a role as well. Newer reports suggest the off-label use

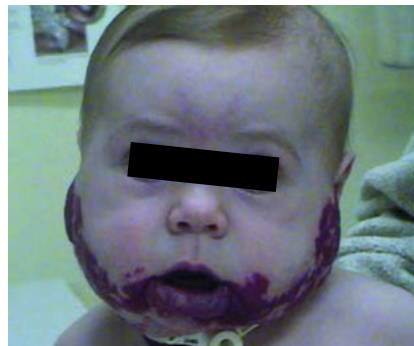

Figure 18.3.

This young child has a large hemangioma with cosmetic as well as functional symptoms.

of systemic propranolol may significantly impact this disease process. Some pediatric otolaryngologists will do laser therapy without performing a tracheotomy, while others prefer to have a tracheotomy. Obviously, this also depends on the size of the lesion relative to the airway. Spontaneous involution usually will occur, but not until the child is 12–24 months of age. In the past, physicians used this fact when advocating for tracheotomy, noting that most children will be decannulated around this age.

Vascular Rings

Yet another cause of stridor in children is **vascular rings**, which may also be accompanied by periods of apnea. Compression of the trachea is caused by either the innominate artery or any number of mediastinal vascular rings that can occur embryologically. For example, a double-arched aorta may compress both the esophagus and the trachea. This diagnosis is generally made by visualizing an anterior compression of the trachea on bronchoscopy. A barium swallow will occasionally show an indentation behind the esophagus if there is a complete vascular ring present that encircles the esophagus and the trachea. The definitive diagnosis is made with either a CT scan or an MRI of the chest. If the symptoms are severe enough, treatment can include ligation and division of the offending vessel or rerouting. These conditions are fairly rare.

Laryngomalacia

The most common cause of persistent stridor in infants is **laryngomalacia**. Classically, this is associated with floppy supraglottic structures and an omega-shaped epiglottis. The noise is thought to be due to high-speed airflow through the narrow, redundant tissue of the supraglottic area. The diagnosis is established by flexible laryngoscopy performed at bedside, but synchronous lesions of the airway have been reported in up to 20 percent of patients. Some otolaryngologists advocate complete bronchoscopic evaluation of the airway to evaluate for these additional lesions. If there is no history of respiratory distress (apnea, cyanosis, retractions) and the patient is gaining weight well, treatment is simply observation, because these children will usually grow out of the condition. If the patient has apneic episodes or desaturates, then the supraglottic tissues can be trimmed or a tracheostomy can be performed. Other indications for surgical intervention include poor weight gain or failure to thrive. Interestingly, recent reports would indicate an association between GERD and laryngomalacia. In symptomatic children, empiric treatment of GERD may result in improvement.

Neck Mass

Another common reason for pediatric patients to see an otolaryngologist is the presence of a **neck mass**. Neck masses in children are most likely to be benign. They can be divided into **congenital, infectious, and neoplastic** categories.

Congenital Neck Masses

One of the common congenital neck masses is a **lymphatic malformation**, also known as a **lymphangioma or cystic hygroma**. It can be massive and can extend up into the floor of the mouth or into the airway. These patients may need immediate intubation or a surgical airway at birth if the neck mass is large enough to cause obstruction. Otherwise, the hygroma can usually be treated with elective surgery or sclerotherapy.

Another common cause of a neck mass in children is a **branchial cleft cyst**. These are characteristically found along the anterior border of the sternocleidomastoid muscle. The cyst can occasionally become infected and swell, only to respond to antibiotic therapy, shrink, and then recur.

Thyroglossal duct cysts can also cause neck masses in children. These occur in the midline, usually over the thyrohyoid membrane. They are usually associated with the hyoid bone and move with swallowing. Treatment is surgical excision with a **Sistrunk operation**, where the mid-portion of the hyoid bone is removed along with the cyst's stalk to the base of the tongue.

Infectious Neck Masses

Infectious causes of neck masses in children are more common than congenital causes. Perhaps the most common reason for enlarged lymph nodes in a child is tonsillitis or pharyngitis. Occasionally, the lymph nodes themselves can become infected, usually with *Staphylococcus* or *Streptococcus* species (**cervical adenitis**). Patients are usually febrile, and the nodes are tender to palpation. Occasionally, these lymph nodes may suppurate and require surgical drainage. You should always consider cat-scratch disease or atypical mycobacterial infection, when children present with **suppurative adenitis** without associated constitutional symptoms (fever, malaise, and

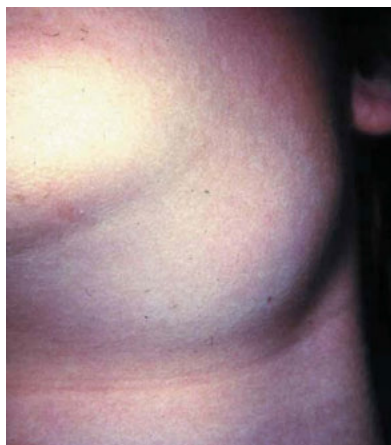

Figure 18.4.

Neck masses arising in children are usually benign (as opposed to adults, in whom they are usually malignant). This is a cystic hygroma, a congenital malformation of lymphatic vessels.

localized tenderness). The patient's history of being scratched by a kitten is the key to making the diagnosis in cat-scratch disease. However, sometimes the child is unaware of the incident.

Atypical mycobacterial infection is occasionally a cause of swollen lymph nodes in children. Generally, this is confined to levels 1 and 2 of the neck. The nodes are not usually painful, and the patient is not toxic. In atypical **tuberculosis** (TB), the lymph nodes follow a somewhat predictable course, wherein the skin overlying the lymph node becomes red and the lymph node appears to “stick to the skin.” This may eventually lead to spontaneous drainage. Excision of the lymph nodes is indicated if they do not respond to medical therapy.

Another condition that must be considered in a child with swollen lymph nodes is TB. Classically, this presents as a collection of matted lymph nodes. The old word for TB lymph nodes in the neck was “scrofula.” Workup includes a chest x-ray, a purified protein derivative test, and a fine-needle aspirate. In this case, the nodes are not treated with excision, but with standard anti-TB medications.

Retropharyngeal cellulitis or abscess is an important infection in children. This is essentially a cervical adenitis that occurs in the space behind the pharynx. These patients may have an obvious amount of inflammation on the anterior spinal ligament, as well as up around the base of the skull, and can therefore present with a stiff neck (**meningismus**) and fever. It may be difficult to discriminate between this disease and meningitis. A soft-tissue lateral neck x-ray will usually show an increased thickness of the retropharyngeal space anterior to the spine. A CT scan with contrast is useful to image the exact location of the abscess or infected lymph node, which is then treated with intravenous antibiotics. Cellulitis will respond to antibiotics, but abscesses frequently require surgical incision and drainage, through either the mouth or the neck. Antibiotic coverage should include coverage for *S. aureus* organisms, anaerobes, and *H. influenzae* infection. Often, there is concern about the possibility of meningitis, so a drug that penetrates the CSF should be used. Choices include cefuroxime or ticarcillin and clavulanate. Vancomycin should be considered if resistant organisms, such as penicillin-resistant *S. pneumoniae*, are suspected.

Malignant Neck Masses

Malignant neck masses in children are rare, and include salivary gland malignancy, which is treated surgically. Tumors of the thyroid gland also occur, and may be accompanied by metastatic disease in the lymph nodes. **Lymphoma**, especially Hodgkin's, can present as cervical adenopathy.

Congenital Nasal Mass

Very rarely, a child may be born with a congenital mass between the eyes and over the bridge of the nose (**nasion**). This can be either a **dermoid cyst** or a **congenital herniation of the intracranial tissues (encephalocele or meningoencephalocele)**. **Heterotopic brain tissue**, called glioma, is also possible, and may not have a connection to the CNS. In making your diagnosis, you should obtain a CT scan to see if there is a **bony defect**. An MRI scan may also be helpful to determine whether there is simply a residual cord of tissue, or whether there is a defect that allows either the meninges alone or the meninges and brain to protrude through the defect. These patients should be referred for surgical excision, along with neurosurgical consultation as indicated.

Tongue Tie

Not uncommonly, children will have a very short lingual frenulum that limits tongue mobility. This makes it especially hard to make certain sounds like “L” (and to eat an ice cream cone), but is easily corrected by incising the frenulum. It may present as difficulty in breast feeding in a neonate.

Rhinosinusitis

All children (and adults) suffer from an occasional bout of rhinosinusitis. Most of these are viral, are of short duration, and require no therapy. Parents, however, can demand antibiotic treatment because of the nasal drainage (often green, yellow, or gray), and when they cannot leave their sick child in daycare. It is important to reassure parents that these episodes are normal, and to resist the temptation to treat mucus with antibiotics. Some children, however, will have persistent illness that lasts for weeks or months and is associated with fever. These patients may benefit from antibiotics directed toward common pathogens. Also, some children will benefit from adenoidectomy, and occasionally sinus aspiration or even surgery may be required.

Rarely, sinus infection can spread into the peri- and intraorbital tissues. If an abscess develops with visual change, **proptosis**, or loss of normal eye movement, urgent surgical drainage is required to prevent loss of vision. A diagnostic CT scan is required in suspected cases. These abscesses can often be drained successfully through an endoscopic approach, but an external incision (just medial to the medial canthus) may be required.

QUESTIONS

1. Four indications for performing tonsillectomy are _____, _____, _____, and _____.
2. A two-year-old boy presents with otitis media with effusion. The fluid has been present in his ears for three months, despite treatment with a three-week course of trimethoprim and sulfamethoxazole. His mother says that he is having trouble hearing. He has had one set of PE tubes in the past. You plan to place another set of PE tubes, and at this time you think that the child may also benefit from an _____.
3. Unilateral, foul-smelling rhinorrhea in a child is most commonly due to a _____.
4. A four-year-old girl presents at the emergency room with inspiratory stridor and a fever of 103°F, and she is drooling and leaning forward. Her mother states that the child was well four hours ago, and she thinks that the child swallowed a stick because her throat hurts now and she was playing with small sticks in the yard outside. Your first concern is that this child may have _____.
5. You then call the anesthesiologist and pediatrician, but while waiting for them to arrive, you notice that the child is starting to tire out. In fact, she becomes so tired from trying to breathe that she simply faints and ceases all attempts at respiration. The first thing you do for this child is _____.
6. Your next patient in the emergency room is a one-year-old boy who presents with a chief complaint of stridor. He had a cold during this past week. On examination, he is not sitting up or leaning forward, and he is not drooling, but he has biphasic stridor. He does not have a fever, but he has a barking cough. The most likely diagnosis in this case is _____.
7. You therefore obtain a soft-tissue x-ray of the neck and a chest x-ray to look for the classic steeple sign. You are surprised when you find the child has actually aspirated a small metal object that appears to be the tip of a pen. Removal is with a rigid _____.
8. A multiloculated cystic neck mass in a newborn child that transilluminates is most probably a _____.
9. A midline neck mass in a child that moves when the child sticks out his tongue, but is otherwise not tender and is found in the area of the hyoid bone, is most probably a _____.

10. A two-year-old child presents to you with a high fever and large, painful, and inflamed left posterior triangle lymph nodes. The most likely diagnosis is _____.
11. Another two-year-old child presents without fever and with no pain, but with large, firm lymph nodes in the posterior triangle of the neck. There are no lesions in the scalp seen on examination. In fact, the child seems to be almost oblivious to these nodes. The child does not have a cat, and has not been recently scratched by a cat or a dog. The most common cause of this type of neck mass in a child is _____.
12. A two-year-old boy presents to you with a fever of 103°F. His mother says he has not eaten anything all day and has vomited once. His neck is very stiff, and he will not move his head. He has had a cold over the last three to four days. You do an exam and find that his ears are not infected and he will not open his mouth at all, and he still will not move his head. You obtain CSF with a lumbar puncture (after noting the absence of papilledema on physical exam), and you send this to the lab. It returns with normal glucose and protein concentrations and no white blood cells. The opening and closing pressures are normal, and the fluid is clear. Every time you try to look in the patient's throat, he turns away, gags, and screams. You are thinking he may have retro or parapharyngeal cellulites or abscess, so you order a _____.
13. The lateral neck x-ray shows increased soft tissue thickness in the prevertebral area, but the child's head is bent down, and it is somewhat difficult to diagnose a retropharyngeal abscess. The next diagnostic study you need is _____.
14. The CT scan shows a large retropharyngeal node that is rim enhancing and has a central lucency. Appropriate antibiotic coverage for this child would include covering the following organisms: _____, _____, and _____.
15. A two-year-old girl is brought by her mother for treatment of sinusitis. She has been ill for two days and has a low-grade fever. Thick, clear mucus is streaming from both nostrils, and her ears are clear. She is otherwise awake, alert, and in no distress, and the rest of your physical exam is normal. You should _____.

CHAPTER 18

ANSWERS

1. Recurrent tonsillitis, chronic tonsillitis, obstructive sleep apnea, asymmetric tonsils
2. Adenoidectomy
3. Foreign body
4. Acute epiglottitis
5. Bag and mask ventilation
6. Croup
7. Bronchoscope
8. Lymphatic malformation (lymphangioma or cystic hygroma)
9. Thyroglossal duct cyst
10. Cervical adenitis
11. Atypical mycobacterial infection
12. Soft-tissue lateral neck x-ray
13. Neck CT with contrast
14. *S. pneumoniae*, *H. influenzae*, *S. aureus*, anaerobes
15. Reassure the mother and recommend follow-up if symptoms worsen or do not resolve within the next 10–14 days.

The American Academy of Otolaryngology—Head and Neck Surgery Foundation’s educational initiatives are aimed at increasing the quality of patient outcomes through knowledgeable, competent, and professional physicians. The goals of education are to provide activities and services for practicing otolaryngologists, physicians-in-training, and non-otolaryngologists.

The Foundation serves as a primary resource for otolaryngology–head and neck activities and events. These include AcademyU, the Foundation’s online library of expert-developed learning activities; the AAO-HNSF Annual Meeting & OTO EXPO, the world’s largest gathering of otolaryngologists; and other activities, including the Patient of the Month Program and the Home Study Course. Many of the Foundation’s activities are available for AMA PRA Category 1 Credit™.

Visit the Academy’s website, www.entnet.org, to find out how the Academy can assist you and your practice.



AMERICAN ACADEMY OF
OTOLARYNGOLOGY–
HEAD AND NECK SURGERY

F O U N D A T I O N

**American Academy of Otolaryngology—Head and Neck
Surgery Foundation**

1650 Diagonal Road

Alexandria, VA 22314-2857 USA

T / 1.703.836.4444

F / 1.703.683.5100

www.entnet.org